

## CASE REPORT

# Rare clinical case report of a contralateral effect of laser biostimulation on the bone regeneration

Ghassan Habash<sup>1,2</sup> | Soher Nagi Jayash<sup>3</sup> 

<sup>1</sup>Deanship of Scientific Research, Al-Quds University, Al-Quds, Palestine

<sup>2</sup>Palestinian Association of Dental Implantology, Al-Quds, Palestine

<sup>3</sup>School of Dentistry, University of Birmingham, Birmingham, UK

## Correspondence

Ghassan Habash, Deanship of Scientific Research, Al-Quds University, Al-Quds, Palestine.

Email: ghassan\_habash@hotmail.com

Soher Nagi Jayash, School of Dentistry, University of Birmingham, 5 Mill Pool Way, Edgbaston, Birmingham B5 7EG, UK.

Email: soheernaji20@yahoo.com

## Abstract

This paper describes a unique clinical case of peri-implantitis treated by a laser biostimulation in one side of maxilla and the effect extended to contralateral side in the maxilla. This indicates that low level laser therapy treatment may have some degree of bilateral effects within the orofacial region.

## KEYWORDS

bone regeneration, contralateral effect, laser biostimulation, peri-implantitis

## 1 | INTRODUCTION

Laser biostimulation is the application of light to increase tissue healing, reduce inflammation, and control pain. Low level laser therapy (LLLT) is used in different dental procedures, such as non-surgical and surgical periodontal treatments, and in many clinical conditions, such as peri-implantitis, post-extraction and bone-healing therapy, temporomandibular disorders, hypersensitive dentine, traumatic ulcerations, aphthous ulcers, herpes simplex virus infection of the lips, mucositis, paresthesiae, and trigeminal neuralgia.<sup>1,2</sup> Peri-implantitis is an inflammatory process that affects the tissues around the implant causing bone loss. The regeneration of soft and hard tissues supporting dental implants is required to treat peri-implantitis.<sup>3</sup> The biostimulative effects of LLLT have been shown in the literature,<sup>4-6</sup> and indicates LLLT can be used to enhance wound healing locally and systemically. Previously, we reported the effects of laser therapy on

horizontal bone regeneration around implants.<sup>7,8</sup> In this case report, LLLT treatment was used to treat the bone loss around implant, surprisingly, the affected not only on the treatment side but also the non-treatment side and indicating that there is a generalized effect within the oral region. We aimed to show a rare bilateral bone regeneration around implants treated with LLLT on one side.

## 2 | CASE REPORT

### 2.1 | Methods

The patient was a 20-year-old woman with a diagnosis of peri-implantitis around implant placement in the upper left missing lateral incisor. The case was treated by using pontic site preservation by covering the implant with connective tissue graft and LLLT and the space restored by a minimally prepared resin-bonded bridge. The treatment

This is an open access article under the terms of the Creative Commons Attribution License, which permits use, distribution and reproduction in any medium, provided the original work is properly cited.

© 2022 The Authors. *Clinical Case Reports* published by John Wiley & Sons Ltd.

of this case was previously reported.<sup>8</sup> Briefly, LLLT was applied on the surgical area using 810 nm Diode laser (QuickLase), pulsating wave mode (0.1 W) for 45 s labially and palatally to the treated implant immediately after each surgery, 7 days, 14 days 1 month, and 3 months after the surgeries. The patient was reviewed after 1 year, and cone beam computed tomography (CBCT) was taken. Written informed consent was obtained from the patient to publish this report in accordance with the journal's patient consent policy.

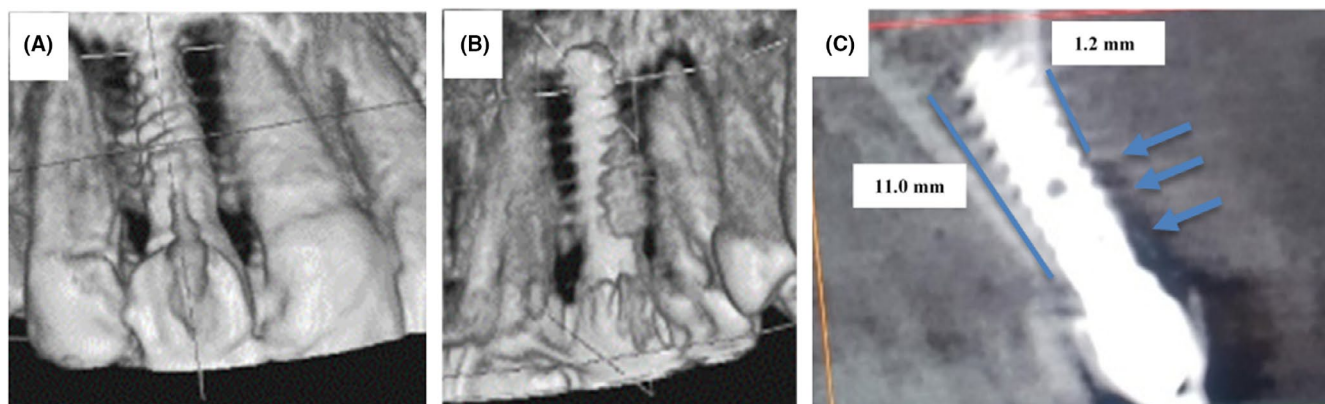
## 2.2 | Results

In the first visit, clinically, the gingiva around implant was normal and there was no pain in the right lateral incisor. CBCT scan revealed bone resorption in mesial and distal surfaces and palatal surfaces around the implant (Figure 1A,B). The main complaint for the patient was in the implant in the contralateral site (left lateral incisor),

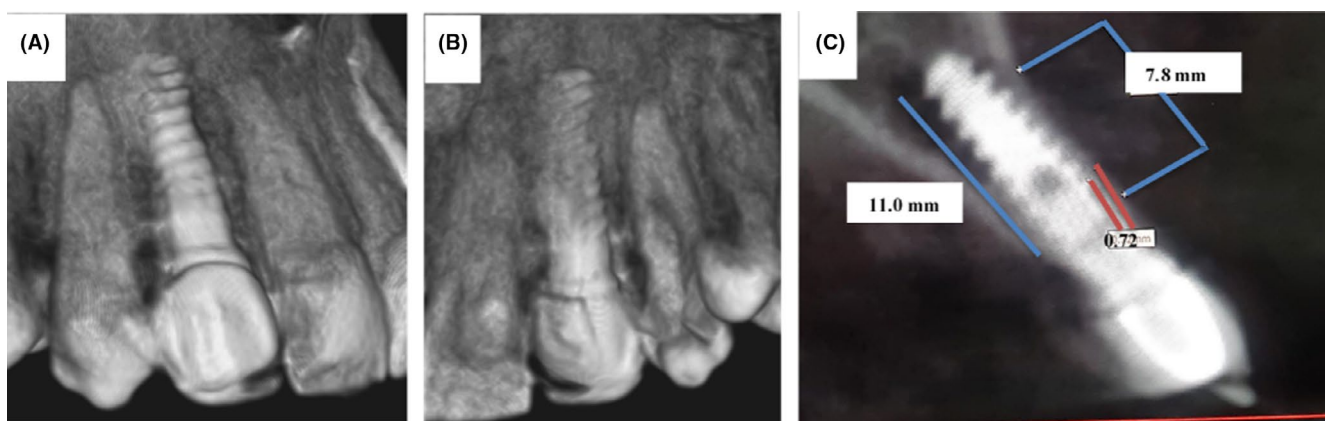
so the laser treatment was not applied on the right lateral incisor. The measurement of bone before treatment was 1.2 mm in the palatal site and 11 mm in the labial site of the implant (Figure 1C). Interestingly, on 1-year evaluation after laser treatment in contralateral site, CBCT showed bone formation around implant in contralateral site (Figure 2A,B). The alveolar bone-height measurements from CBCT images bone were 7.76 mm in the palatal side after treatment (Figure 2C). The bone thickness adjacent to dental implant was 0.72 mm on the palatal site of the implant (Figure 2C).

## 3 | DISCUSSION

The benefit of using laser around the implant over other techniques is their ability to reach hard areas around the implant to achieve better sterilization and debridement. Our previous case report describes the clinical benefits of photobiomodulation in the treatment of peri-implantitis



**FIGURE 1** 3D composition of the implant site before treatment in labial view (A) and palatal view (B). (C) The CBCT imaging of implant site showing the measurements of bone height in labiopalatal view before treatment



**FIGURE 2** 3D composition of the implant site after treatment in labial view (A) and palatal view (B). (C) The CBCT imaging of implant site showing the measurements of bone height in labiopalatal view after treatment

that reported adequate bone fill one year post-operatively after laser therapy. Also, a previous study revealed that photobiomodulation accelerates, in vivo, the healing of the mucosa overlying alveolar sockets and can only hypothesize that also the underlying bone could reform in a shortened time.<sup>9</sup>

Surprisingly, the effect induced by LLLT was not restricted to the treatment side and was also observed on the contralateral side, indicating a bilateral effect in the anterior area of the maxilla. Previously, clinical study reported the application of LLLT appears to reduce the pain and sensitivity of the tooth and gingiva associated with orthodontic treatment and the analgesic effect induced by LLLT was not restricted to the treatment side and was also observed on the contralateral side, indicating an extended effect in the trigeminal area.<sup>10</sup> This indicates that LLLT treatment may have some degree of bilateral effects within the orofacial region. This interesting finding will open the door for additional application of LLLT in bone healing that can be used clinically. However, this is the first clinical study reported the bilateral effect of laser in bone regeneration so this finding calls for future studies on the bilateral effects of LLLT.

## 4 | CONCLUSION

The application of LLLT appears to induce bone regeneration and may have contralateral effects. Thus, the present study indicates an interesting effect of LLLT on bone formation. Further clinical applications are suggested.

### ACKNOWLEDGMENT

The authors would like to thank Dr. Ayman Zaghaf for his assistance in imaging.

### CONFLICT OF INTEREST

The authors declare there are no competing interests.

### ETHICAL APPROVAL AND CONSENT TO PARTICIPATE

Patient consent and ethics approval are not applicable.

### CONSENT

Consent for publication is signed.

### DATA AVAILABILITY STATEMENT

All supporting data are available.

### ORCID

Soher Nagi Jayash  <https://orcid.org/0000-0001-5263-8557>

### REFERENCES

1. Carroll JD, Milward MR, Cooper PR, Hadis M, Palin WM. Developments in low level light therapy (LLLT) for dentistry. *Dent Mater*. 2014;30(5):465-475.
2. Misra N, Chittoria N, Umopathy D, Misra P. Efficacy of diode laser in the management of oral lichen planus. *Case Rep*. 2013;2013:bcr2012007609.
3. Dreyer H, Grischke J, Tiede C, et al. Epidemiology and risk factors of peri-implantitis: a systematic review. *J Periodontol Res*. 2018;53(5):657-681.
4. Hawkins D, Abrahamse H. Phototherapy—a treatment modality for wound healing and pain relief. *Afr J Biomed Res*. 2007;10(2).
5. Bensadoun R-J, Nair RG. Low-level laser therapy in the prevention and treatment of cancer therapy-induced mucositis: 2012 state of the art based on literature review and meta-analysis. *Curr Opin Oncol*. 2012;24(4):363-370.
6. Özberk SS, Gündoğar H, Şenyurt SZ, Erciyas K. Adjunct use of low-level laser therapy on the treatment of necrotizing ulcerative gingivitis: a case report. *J Lasers Med Sci*. 2018;9(1):73.
7. Habash G, Jayash SN. Diode laser assisted horizontal bone defect regeneration in the treatment of peri-implantitis. *Clin Case Rep*. 2021;9(3):1247-1252.
8. Jayash SN, Habash G, Kamal M. Non-conventional method of pontic site preservation with laser-assisted bone regeneration. *Clin Case Rep*. 2021;9(7):e04483.
9. Scarano A, Lorusso F, Postiglione F, Mastrangelo F, Petrini M. Photobiomodulation enhances the healing of postextraction alveolar sockets: a randomized clinical trial with histomorphometric analysis and immunohistochemistry. *J Oral Maxillofac Surg*. 2021;79(1):57.e1-57.e12.
10. Wu S, Chen Y, Zhang J, et al. Effect of low-level laser therapy on tooth-related pain and somatosensory function evoked by orthodontic treatment. *Int J Oral Sci*. 2018;10(3):1-8.

**How to cite this article:** Habash G, Jayash SN. Rare clinical case report of a contralateral effect of laser biostimulation on the bone regeneration. *Clin Case Rep*. 2022;10:e05631. doi:[10.1002/ccr3.5631](https://doi.org/10.1002/ccr3.5631)