

Available online at www.sciencedirect.com

ScienceDirect

journal homepage: www.elsevier.com/locate/radcr

Case Report

Radiological diagnosis of median nerve lipoma: A case report from Palestine ☆,☆☆,★

Oadi N. Shrateh, MD^{a,*}, Afnan W.M. Jobran, MD^a, Mohammed Khatib, MD^b, Sa'd Sulaiman, MD^b, Fadi Thalji, MD^c, Sami Hussein, MD^{d,e}

^a Medical Research Club, Faculty of Medicine, Al-Quds University, 48-Main Ramallah Street, Ramallah, Palestine

^b Radiology Department, Al-Istishari Arab Hospital, Ramallah, West Bank, Palestine

^c Head of Orthopedic Surgery Department, Al-Istishari Arab Hospital, Ramallah, West Bank, Palestine

^d Head of Neurosurgery Department, Al-Istishari Arab Hospital, Ramallah, West Bank, Palestine

^e Professor at Neuropathology Department, Hannover Medical School, Hannover, Germany

ARTICLE INFO

Article history:

Received 7 December 2022

Revised 22 December 2022

Accepted 27 December 2022

Keywords:

Lipoma

MRI

Median nerve

Limb

ABSTRACT

Lipomas are benign neoplasms that develop from adipocyte-rich adipose tissue. They affect up to 2% of the population and make up about 50% of all soft-tissue neoplasms. The most common locations for them to appear asymptotically are the neck, upper back, proximal limbs, and chest. They typically start off as single, distinct, movable lumps. A 50-year-old man who had pain and edema in his right wrist came to our hospital. The patient's history dates back to 9 years ago, when he first began to complain of swelling in his wrist rest but no discomfort. According to a clinical examination, he has a soft, non-painful bump in his right wrist. After being monitored for 9 years with no change in the size of the tumor on his right wrist, the patient started to experience right hand pain and a weak right grasp. Magnetic resonance imaging is the preferred visualization method for examining hand tumors; it is advised to perform a preoperative complementary ultrasound or magnetic resonance imaging investigation in cases of atypical findings or nonfrequent locations of nerve compression, which are clinically interpreted as idiopathic compression.

© 2022 The Authors. Published by Elsevier Inc. on behalf of University of Washington.

This is an open access article under the CC BY-NC-ND license

(<http://creativecommons.org/licenses/by-nc-nd/4.0/>)

☆ Guarantor: Oadi N. Shrateh

☆☆ Funding: This research did not receive any specific grant from funding agencies in the public, commercial, or not-for-profit sectors.

* Competing Interests: The authors declare that they have no known competing financial interests or personal relationships that could have appeared to influence the work reported in this paper.

* Corresponding author.

E-mail address: oadi.shrateh@students.alquds.edu (O.N. Shrateh).

<https://doi.org/10.1016/j.radcr.2022.12.056>

1930-0433/© 2022 The Authors. Published by Elsevier Inc. on behalf of University of Washington. This is an open access article under the CC BY-NC-ND license (<http://creativecommons.org/licenses/by-nc-nd/4.0/>)

Introduction

Lipomas, which can be seen in about 2% of the population, are one of the most common benign tumors. Most patients are asymptomatic, and lipomas are commonly seen in the neck, upper back, proximal limbs, and chest. Lipomas in the distal extremities can be seen in less than 1% of total lipomas [1]. Adipose lesions of distal extremity nerves are rare, and they are related to 2 main pathways. It can occur as a result of nerve compression caused by an extra-neural lipoma or as a result of a lipoma that originated from the nerve sheath adipose tissue [2]. Intraneural lipomas are rare tumors that most commonly occur in the forearm and wrist, particularly within the median nerve. The term intraneural lipoma means encapsulated lipoma, which can be separated from the surrounding neural structures, and microscopic examination reveals that these lesions are composed of only adipose tissue without neural elements, which is opposite to fibrolipomatous hamartoma, which is composed of fatty and fibrous tissue with intermingling nerve fibers [3]. Magnetic resonance imaging (MRI) is an excellent tool for noninvasive adipose tissue evaluation with respect to distribution, composition, and metabolic activity. Both standard and newly developed MRI techniques can be used for risk stratification for the development of metabolic dysfunction and allow monitoring without the use of ionizing radiation or contrast material [4].

Case presentation

A 50-year-old male presented to our hospital with a case of right wrist swelling and pain. The history of our patient dates back to 9 years ago, when he started to complain of swelling in his wrist with no pain. Clinical examination concluded that he has a soft, non-tender lump in his right wrist. Patient was followed up for 9 years with no change in the size of his right wrist lump. In mid-2022, the patient started to complain of right-hand pain with right grip weakness. After being evaluated by orthopedic and neurosurgery teams, the patient was referred for a wrist MRI, which revealed (Figs. 1-3); a lobulated lesion measuring approximately $3.8 \times 1.5 \times 1.3$ cm was discovered on the anterolateral aspect of the right distal forearm.

The lesion is seen within the sheath of the median nerve; it is located within the lateral part of the nerve and causes nerve fascicles to spread; most fascicles are seen at the lesion's periphery, but a fiber bundle is seen within its center. The lesion shows fat signal on all sequences (high signal on T1WI, high signal on T2WI, and suppression on fat saturation sequences). On postcontrast images, no significant enhancement was observed. It most likely represents an intraneural lipoma; the differential diagnosis includes a focal fibrolipomatous hamartoma of the nerve (as there is a fiber bundle within the center of the lesion).

After that, the patient was referred to the neurosurgery team, where a median nerve lesion was identified and treated with right median nerve lesion excision. The pathology report concluded that the findings of the biopsy were mature fatty tissue consistent with lipoma with no evidence of malignancy. After that, the patient was followed in the clinic with no pain and improvement in his right wrist power.

Discussion

Lipomas are benign tumors that develop from adipose cells and can appear in the paraosteal, intermuscular, or subcutaneous tissues [5]. Giant lipomas (lipomas larger than 5 cm in diameter) are uncommon in the upper limb [6]. Masses are typically symptomatic at a lesser size in this anatomic region. Although subfascial lipomas are deep tumors that can cause nerve compression, nerve compression caused by a lipoma is not common [5].

Ten giant lipomatous tumors, 7 lipomas, one neural fibrolipoma, and 2 well-differentiated liposarcomas were described by Cribb et al. [6]. Five of the tumors were found in the hand and 5 in the forearm. Two of the tumors showed signs of median nerve compression, one in the hand and the other's exact location being unknown. However, in each case, it was necessary to mobilize the neurovascular structures in order to remove the tumor. Giant soft tissue tumor investigations should use a multidisciplinary strategy, according to Cribb et al. [6], who also recommended doing routine MRIs. They went on to recommend that a biopsy be done in cases where an MRI does not clearly show a lipoma or in patients who could not bear the inquiry. According to Johnson et al. [7]'s re-

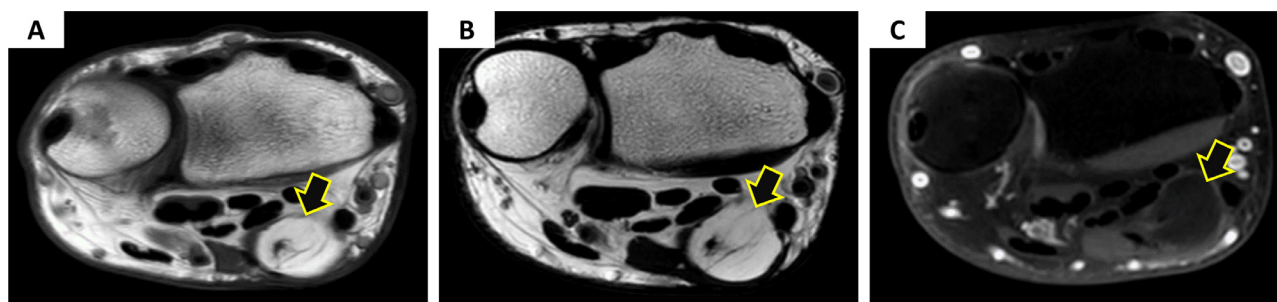


Fig. 1 – (A & B) are axial T1WI and T2WI images, respectively, showing a high-signal intensity lesion (isointense to subcutaneous fat) seen in the median nerve with the central nerve bundle. (C): An axial T1 SPIR image showing homogenous fat suppression of the lesion (arrows).

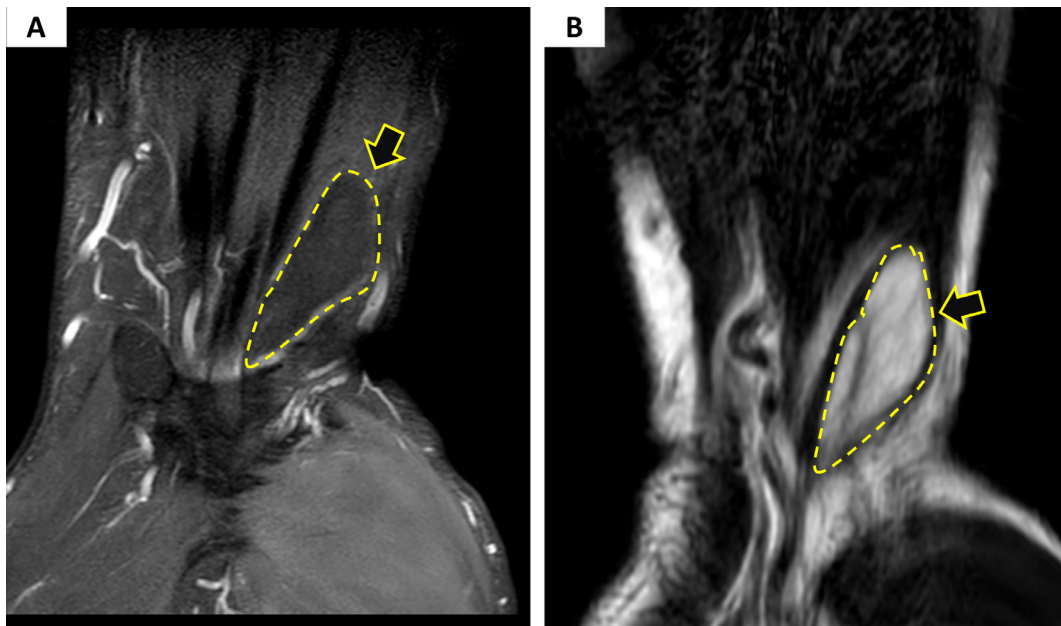


Fig. 2 – (A) A coronal PDW-SPAIR image showing a low signal intensity lesion inside the median nerve. **(B)** A coronal T2WI image showing a high-signal intensity lesion inside the median nerve (arrows & dash lines).

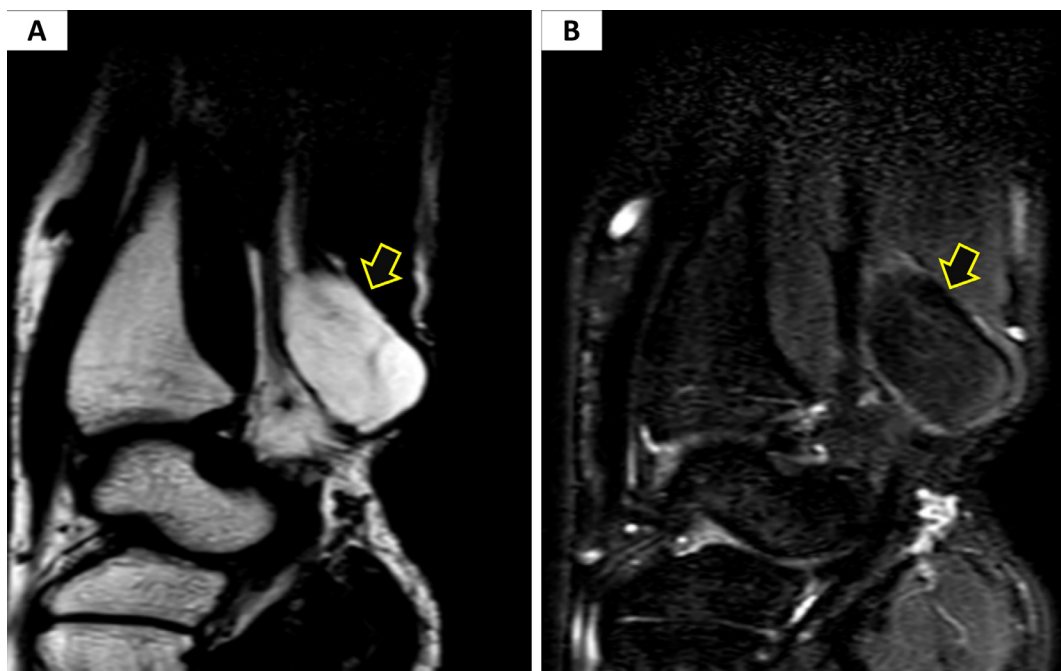


Fig. 3 – (A & B) Sagittal T2WI without and with fat saturation, respectively, showing a homogenous fat suppression of the lesion. The findings are consistent with a fat-containing lesion within the median nerve (arrows).

search, soft tissue tumors larger than 5 cm in diameter should be assumed to be malignant unless otherwise confirmed.

The forearm and wrist are the most typical sites for intraneural lipomas and lipofibroma (librofibromatous hamartomas), which are uncommon benign adipose tumors of peripheral nerves. Mason [8] initially described a lipofibroma in 1953. Morley described the first intraneural lipoma in 1964

[9]. These masses may exhibit a similar clinical presentation. Intraneural lipomas and lipofibromas, however, differ significantly [10]. Intraneural lipomas are often well-defined, encapsulated tumors that interfere with nerve function rather than invading it. On the other hand, fatty and fibrous tissue make up lipofibromas, which are diffusely infiltrative. These lesions are treated differently according to their various pathological

characteristics. The 2 entities can be distinguished using MRI, which serves as a diagnostic tool [11].

Adipose lesions of the nerve typically manifest as asymptomatic or barely noticeable swelling because of their sluggish growth [12]. Nerve lipomas rarely present with severe nerve impairment [12]. Patients with unilateral carpal tunnel syndrome and anomalies in nerve conduction should be evaluated for medial nerve lipoma [13]. It is well recognized that the majority of instances of bilateral carpal tunnel syndrome are idiopathic. Patients with unilateral carpal tunnel syndrome had a higher prevalence of space-occupying lesions, according to Nakamichi and Tachibana [14]. In 2 cases, individuals with unilateral carpal tunnel syndrome had concealed palmar lipomas that were compressing the median nerve, according to Bagatur and Yalcinkaia [13].

The preferred visualization technique for investigating hand cancers is MRI. Capelastegui et al. compared the results of MRI with those of histopathology in a series of 134 instances of hand and wrist cancer and came to the conclusion that MRI had a positive predictive value of 94% [15]. Adipose tumors typically present as a homogeneous mass with a crisp boundary, high T1 and T2 signal intensity, decreasing signal intensity following erasure of the fat signal, and no gadolinium contrast agent enhancement [16, 17]. Lesions having a fibrous component can show a heterogeneous signal, as was the case in our case. To distinguish between intraneural lipomas, lipomatosis of the nerve, and other lesions affecting the peripheral nerves, MRI is the most effective noninvasive exam. When a nerve is damaged by lipomatosis, it enlarges the affected nerve diffusely, and the thicker fascicles take on a cable-like or spaghetti-like appearance due to fatty and fibrous infiltration [18]. Additionally, it aids in surgical planning once the tumor's size and relationship to crucial tissues are revealed [19]. Recently, a few authors have discussed their experience using ultrasonography for the intraoperative identification and therapy of peripheral nerve lesions [20]. The technique can be used to more precisely pinpoint both healthy and pathological anatomy, and it is especially helpful when there are several lesions, small lesions, deep or elusive nerves, or when a region has had surgery or been injured [20]. As mentioned by Halde- man et al. [20], it is anticipated that in the near future, advancements in high-resolution ultrasonography will allow for the definition of both the intraneural anatomy and the nerves and their pathology in order to improve the results of nerve tumors.

Conclusion

The spectrum of adipocytic tumors includes highly aggressive liposarcomas and benign fat-containing tumors (LPSs). Lipoma, lipoblastoma, myolipoma, chondroid lipoma, spindle cell lipoma, lipomatosis, and hibernoma are benign adipocytic tumors. It is advised to perform a preoperative supplementary ultrasound or magnetic resonance imaging (MRI) scan in cases of unusual findings or a non-frequent location of nerve compression.

Authors' contributions

Writing the manuscript: Oadi N. Shrateh, Afnan W.M. Jobran, Mohammed Khatib; Imaging description: Mohammed Khatib, Sa'd Sulaiman; Reviewing & editing the manuscript: Oadi N. Shrateh, Fadi Thalji, Sami Hussein

Authorship

All authors attest that they meet the current ICMJE criteria for authorship.

Patient consent

Written informed consent to publish this case and use anonymized radiologic material was obtained from the patient.

REFERENCES

- [1] Clesham K, Galbraith JG, Ramasamy A, Karkuri A. Giant lipoma of the hand causing median nerve compression. *Case Rep* 2017;2017:1–3.
- [2] Teles A, Finger G, Schuster M, Gobbato P. Peripheral nerve lipoma: Case report of an intraneural lipoma of the median nerve and literature review. *Asian J Neurosurg* 2016;11(04):458.
- [3] Okubo T, Saito T, Mitomi H, Takagi T, Torigoe T, Suehara Y, et al. Intraneural lipomatous tumor of the median nerve: Three case reports with a review of literature. *Int J Surg Case Rep* 2012;3(9):407–11.
- [4] Franz D, Syväri J, Weidlich D, Baum T, Rummeny EJ, Karampinos DC. Magnetic resonance imaging of adipose tissue in metabolic dysfunction. *RöFo-Fortschritte auf dem Gebiet der Röntgenstrahlen und der bildgebenden Verfahren* 2018;190(12):1121–30 © Georg Thieme Verlag KG.
- [5] Leffert RD. Lipomas of the upper extremity. *JBJS* 1972;54(6):1262–6.
- [6] Cribb G, Cool WP, Ford DJ, Mangham DC. Giant lipomatous tumours of the hand and forearm. *J Hand Surg* 2005;30(5):509–12.
- [7] Johnson CN, Ha AS, Chen E, Davidson D. Lipomatous soft-tissue tumors. *JAAOS-J Am Acad Orthop Surg* 2018;26(22):779–88.
- [8] Mason M. Presentation of cases. *J Bone Joint Surg* 1953;35:273–4.
- [9] Morley GH. Intraneural lipoma of the median nerve in the carpal tunnel. *J Bone Joint Surg Br Vol* 1964;46(4):734–5.
- [10] Spinner RJ, Scheithauer BW, Amrami KK, Wenger DE, Hébert-Blouin MN. Adipose lesions of nerve: the need for a modified classification. *J Neurosurg* 2012;116(2):418–31.
- [11] Marom EM, Helms CA. Fibrolipomatous hamartoma: pathognomonic on MR imaging. *Skelet Radiol* 1999;28(5):260–4.
- [12] Gennaro S, Meriadri P, Secci F. Intraneural lipoma of the median nerve mimicking carpal tunnel syndrome. *Acta Neurochir (Wien)* 2012;154(7):1299–301.

-
- [13] Bagatur AE, Yalcinkaya M. Unilateral carpal tunnel syndrome caused by an occult palmar lipoma. *Orthopedics (Online)* 2009;32(10):777.
- [14] Nakamichi K, Tachibana S. Unilateral carpal tunnel syndrome and space-occupying lesions. *J Hand Surg Br Eur Vol* 1993;18(6):748–9.
- [15] Capelastegui A, Astigarraga E, Fernandez-Canton G, Saralegui I, Larena JA, Merino A. Masses and pseudomasses of the hand and wrist: MR findings in 134 cases. *Skelet Radiol* 1999;28(9):498–507.
- [16] Ergun T, Lakadamyali H, Derincek A, Tarhan NC, Ozturk A. Magnetic resonance imaging in the visualization of benign tumors and tumor-like lesions of hand and wrist. *Curr Probl Diagn Radiol* 2010;39(1):1–16.
- [17] Goodwin R, O'Donnell P, Saifuddin A. MRI appearances of common benign soft-tissue tumours. *Clin Radiol* 2007;62(9):843–53.
- [18] Ahlawat S, Chhabra A, Blakely J. Magnetic resonance neurography of peripheral nerve tumors and tumorlike conditions. *Neuroimaging Clin* 2014;24(1):171–92.
- [19] Pagonis T, Givissis P, Christodoulou A. Complications arising from a misdiagnosed giant lipoma of the hand and palm: a case report. *J Med Case Rep* 2011;5(1):1–5.
- [20] Haldeman CL, Baggott CD, Hanna AS. Intraoperative ultrasound-assisted peripheral nerve surgery. *Neurosurg Focus* 2015;39(3):E4.