



Case report

A case of uniportal VATS thymectomy for Thymoma associated with myasthenia gravis and toxic multinodular goiter

Osama N. Dukmak^{a,*}, Ruba Dweik^a, Nadeen Hashlamoun^a, Rahaf Qawasmeh^a,
 Mohammad Eid Al Mohtasib^b, Yousef Abu Asbeh^b

^a Faculty of Medicine, Al-Quds University, West Bank, Palestine

^b Thoracic Surgery Unit, Al Ahli Hospital, West Bank, Palestine

ARTICLE INFO

Keywords:

Thymoma
 Myasthenia gravis
 Uniportal VATS
 Toxic multinodular goiter
 Case report

ABSTRACT

Background: Thymoma is a rare neoplasm, which may be associated with autoimmune disorders, the occurrence of hyperthyroidism in the patients with thymoma is rare.

Clinical presentation: Here we present an extremely rare case of a 56-year-old female patient who was discovered to have malignant thymoma with associated myasthenia gravis and hyperthyroidism due to toxic multinodular goiter. Our patient started to complain of difficulty breathing and swallowing, Chest CT scan was done and revealed an anterior mediastinal mass, measures about $4.1 \times 3.1 \times 2.2$ cm with enlarged lymph node mostly representing thymoma.

Complete thymectomy was performed via uniportal video-assisted thoracoscopic surgery, and the patient's postoperative recovery was uneventful. Microscopic histopathology findings corresponded to thymoma type B1.

Conclusion: The coexistence of thymoma, MG and toxic multinodular goiter is extremely rare. MG should always be suspected in a patient with thymoma. VATS thymectomy has been increasingly used to treat thymoma as it has several advantages over open surgery.

1. Introduction

Thymomas are a rare type of tumor that arises from the epithelial cells of the thymus gland, they are also the most common mediastinal masses in adults, making up 50% of anterior mediastinal masses [1].

In a study of 283 patients with thymomas, 52% had a paraneoplastic autoimmune syndrome, including myasthenia gravis, autoimmune thyroid disease, and other autoimmune disorders [2]. As many as 75–80% of Myasthenia graves patients have thymic abnormalities [1].

In general, thymoma is likely associated with other autoimmune disorders like autoimmune thyroid disorders but in this case report, we present a 56-year-old female patient, a known case of toxic multinodular goiter who had a new onset of symptomatic thymoma associated with myasthenia gravis, with negative laboratory results of all antithyroid antibodies. Furthermore, we present the unfamiliar associations that exist between thymoma and its related clinical syndromes.

This case report has been reported in line with the SCARE Criteria [3].

2. Case report

A 56-year-old female patient, a known case of DM, dysrhythmia and hyperthyroidism, was in her usual state of health until 1 year ago when she complained of easy fatigability, depressed mood and difficulty breathing, brain MRI was done and was free, workup and assessment by a neurologist led to her diagnosis of myasthenia gravis that was managed with pyridostigmine and Azathioprine, and most of her symptoms controlled with these medications.

Seven months later, her past symptoms worsened with unintentional weight loss (about 6 kg during the past two months), cough and sweating. The patient underwent a chest CT scan which revealed an oval-shaped, solid, hypodense mass in her anterior mediastinum, measuring about $4.1 \times 3.1 \times 2.2$ cm mostly representing thymoma (Fig. 1), the patient was referred to a thoracic surgeon for thymectomy.

Her past medical history includes a history of diabetes mellitus, hypertension, dysrhythmia and hyperthyroidism. Her condition is controlled by medications.

The patient's vital signs were within normal range, she looks well,

* Corresponding author at: Al-Quds University, College of Medicine, Main Campus, Abu dis, P.O. Box 89, Palestine.

E-mail address: Osama.dukmak112@hotmail.com (O.N. Dukmak).

<https://doi.org/10.1016/j.ijscr.2022.107183>

Received 19 April 2022; Received in revised form 6 May 2022; Accepted 8 May 2022

Available online 11 May 2022

2210-2612/© 2022 The Authors. Published by Elsevier Ltd on behalf of IJS Publishing Group Ltd. This is an open access article under the CC BY license (<http://creativecommons.org/licenses/by/4.0/>).

not in pain or distress, spoke nasally, had a dropped eyelid, no exophthalmos, no puffy eyes no diplopia, no onycholysis, no acropachy, no pretibial myxedema and no visible neck masses or swelling. Neurological, respiratory, and cardiac examinations were non remarkable.

Laboratory evaluation for the patient was done and showed thyroid stimulating hormone = 0.08 uIU/mL (normal range 0.4–4.94 uIU/mL), free T3 = 2.3 PG/mL (normal range 1.71–3.71 PG/mL), free T4 = 1.5 ng/dL (normal range 0.7–1.5 ng/dL), TSH receptor antibody = 0.5 IU/mL (normal range 0–1 IU/mL), thyroglobulin antibody = 1.15 IU/mL (normal range 0–4.11 IU/mL), antithyroid peroxidase antibody = 2.26 IU/mL (normal range 0–5.6 IU/mL), acetylcholine receptor antibody >8 nmol/L (normal range < 0.5 nmol/L), CBC, PT, PTT, INR, liver function tests were within normal range.

Neck ultrasound showed Few bilateral spongiform thyroid nodules, the largest measuring 10x7mm and seen at the right side. Few bilateral benign-looking enlarged cervical lymph nodes were present suggesting multinodular goiter.

The patient had controlled hyperthyroidism on Methimazole (Thiamazole) for five years (Normal TSH, Normal T3, T4), and was seen perioperatively by our endocrinologist. She repeated the investigations (TSH, T3, T4,) and all were within normal range, and the plan was to continue on same medication (Methimazole) during the perioperative period.

Also, the patient was seen by our medical team and they discontinued the Aspirin five days preoperatively. She was kept on Clexane from post-operative day one till the day of discharge home based on our hospital protocol. She was discharged home on Aspirin.

The patient underwent an elective right unipolar VATS surgery using single port incision 3 cm in the anterior axillary line, in which anterior mediastinal mass measuring about 4.1 * 3.1 * 2.2 cm was removed (Fig. 2) together with the surround pericardial fat. After that, she was transferred to the surgical ICU for close observation. The patient was discharged in post-operative day three with no other complications and in good health. Thyroidectomy was not done because the patient's symptoms were controlled by one medication and there was no clear indication for Thyroidectomy.

Histopathological examination of the thymectomy specimen (Fig. 3) showed a predominance of lymphocytes with the presence of paler areas and perivascular spaces. Two lymph nodes were examined and showed no evidence of tumor.

3. Discussion

Thymomas are the most common mediastinal tumors, they have a spectrum of presentations ranging from an asymptomatic mass to

extensive tumor [4]. They have a peak incidence in the fourth and fifth decades of life with equal male to female ratio [4]. Thymomas are frequently associated with paraneoplastic syndromes most commonly being the Myasthenia gravis (MG) [4].

MG is an autoimmune disorder characterized by a defect in nerve impulse transmission to muscles leading to abnormal fatigability and muscle weakness [5]. Its well-recognized that MG may coexist with other autoimmune disorders, including the autoimmune disorders of the thyroid [5,6].

It's estimated that around 15% of patients with MG have thymomas [7]. Nevertheless, around half of the patients with thymoma will develop MG [7]. We conclude that MG has been linked to both thymomas and thyroid disorders. Herein, we report a patient with malignant thymoma having both MG and hyperthyroidism secondary to toxic multinodular goiter. It's extremely rare for these three diseases to occur together and we were able to find only one case reported in the literature having MG with thymoma and toxic multinodular goiter [8].

The patient underwent VATS thymectomy which has been used increasingly worldwide as it has shown to have similar or higher five-year survival rate when compared to open thymectomy for thymomas [9]. It has also been shown that VATS patients had shorter hospital period and lower blood loss intra-operatively and a lower rates of pneumonia post-operatively [9–12]. On the other hand, VATS thymectomy had higher incidence of phrenic nerve injury compared to open surgery [9–12]. Our patient was discharged home in a good health with no post-operative complications.

The following table describes some advantages and disadvantages of VATS thyroidectomy when compared to open surgery for treating thymoma.

The five year survival rate for thymomas is around 73% [13]. Age is an independent prognostic factor in which older ages carry a worse prognosis. In addition, Patients who have both Thymoma and MG carry a worse prognosis than patients who have only thymoma [14].

4. Conclusion

The coexistence of thymoma, MG and toxic multinodular goiter is extremely rare. MG should always be suspected in a patient with thymoma. VATS thymectomy has been increasingly used to treat thymoma as it has several advantages over open surgery.

Ethical approval

The study is exempt from ethical approval at our hospital.

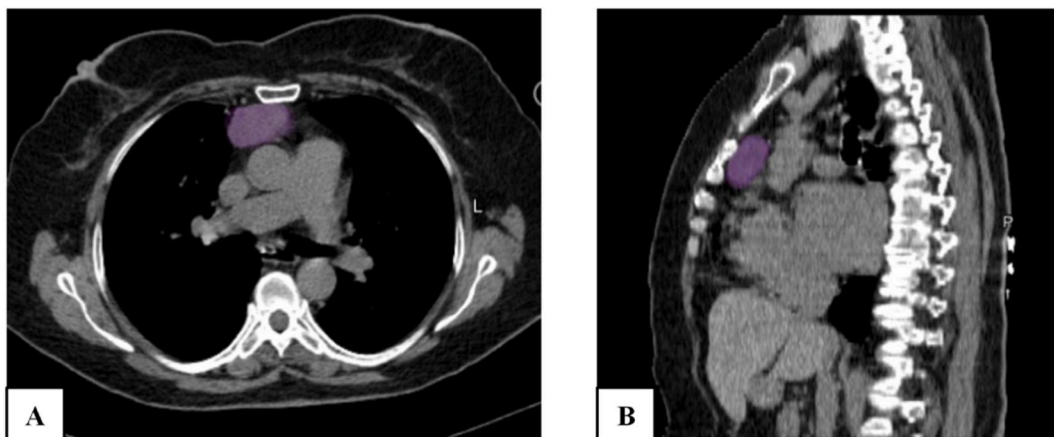


Fig. 1. Chest CT scan A: oval-shaped, solid, hypodense anterior mediastinal mass, measuring about 4.1 × 3.1 × 2.2 cm with enlarged lymph node mostly representing thymoma. B: Sagittal section showing oval-shaped hypodense thymoma with the previously mentioned measures, with close relation to the mediastinal structures.

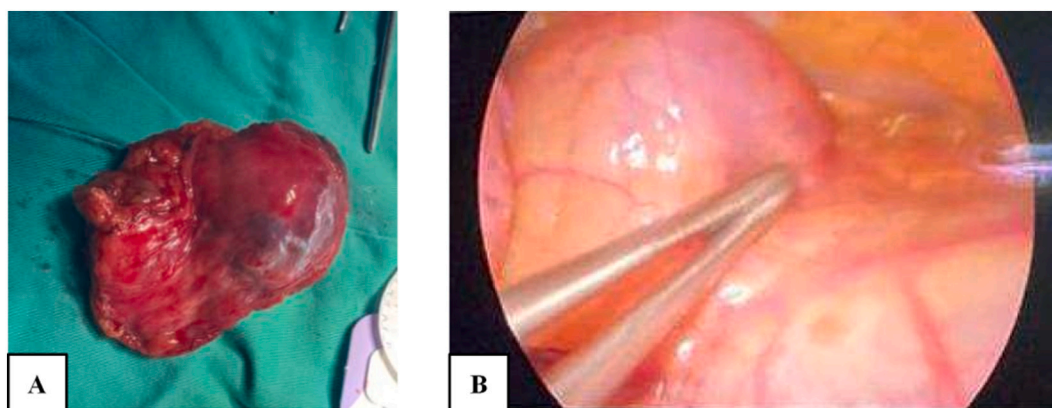


Fig. 2. Gross view for thymoma A: Anterior mediastinal mass measured about 4.1 * 3.1 * 2.2 cm was removed through Uniportal VATS. Histopathology revealed thymoma type B1, all margins are negative for the tumor. B: Thoracoscopic view of the thymoma.

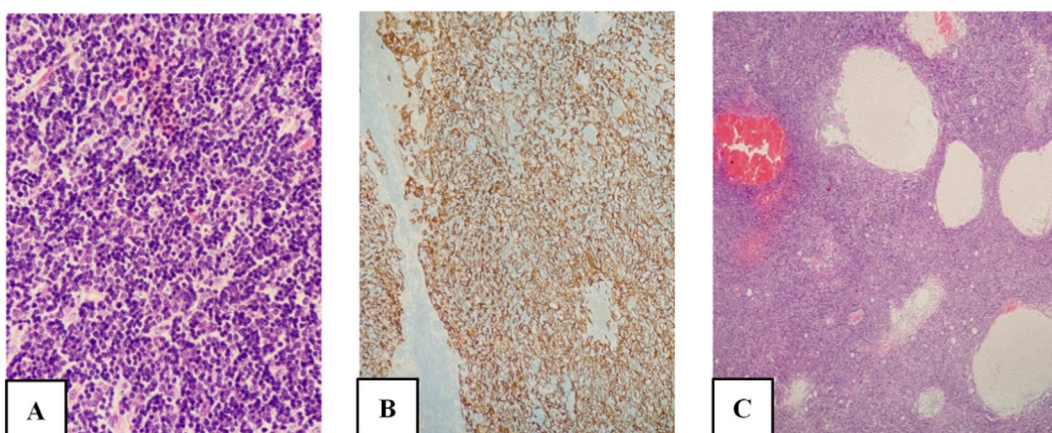


Fig. 3. Histopathology of thymectomy specimen showing
 A: CK AE1/3 highlights the diffuse meshwork of the neoplastic epithelial cells.
 B: predominance of lymphocytes and only scattered visible neoplastic epithelial cells (40 \times , magnification)
 C: Thymoma B1, showing a predominance of lymphocytes with the presence of paler areas (grey) and perivascular spaces (blue). (H&E;10 \times Magnification). (For interpretation of the references to colour in this figure legend, the reader is referred to the web version of this article.)

Source of funding

We did not receive any funding for this article.

Guarantor

Dr. Yousef Abu Asbeh

Trial registry number

The study does not have a trial registry number.

Consent form

We obtained verbal and written informed consent from the patient for this case report. A copy of the written consent is available for review by the Editor-in-Chief of this journal on request.

Provenance and peer review

Not commissioned, externally peer-reviewed.

CRediT authorship contribution statement

Data collection: Yousef Abu asbeh, Mohmmad Al Mohtasib
 Study concept or design: Osama N. Dukmak, Yousef Abu Asbeh
 Writing the manuscript: Osama N. Dukmak, Ruba Dweik, Nadeen Hashlamoun, Rahaf qawasmeh
 Review & editing the manuscript: Osama N. Dukmak, Yousef abu Asbeh,
 Histopathological Interpretation: Sami Bannoura

Declaration of competing interest

There are no conflicts of interest to declare by the authors.

Acknowledgment

The authors are thankful for the patient and his family for their great cooperation.
 The authors would also like to thank Dr. Sami Bannoura for his help in histopathological interpretation.

References

- [1] C. Bernard, H. Frih, F. Pasquet, S. Kerever, Y. Jamilloux, F. Tronc, B. Guibert, S. Isaac, M. Devouassoux, L. Chalabreysse, C. Broussolle, P. Petiot, N. Girard,

- P. Sève, Thymoma associated with autoimmune diseases: 85 cases and literature review, *Autoimmun. Rev.* 15 (2016) 82–92, <https://doi.org/10.1016/j.AUTREV.2015.09.005>.
- [2] Y. Levy, A. Afek, Y. Sherer, Y. Bar-Dayyan, R. Shibi, J. Kopolovic, Y. Shoenfeld, Malignant thymoma associated with autoimmune diseases: a retrospective study and review of the literature, *Semin Arthritis Rheum.* 28 (1998) 73–79, [https://doi.org/10.1016/S0049-0172\(98\)80039-5](https://doi.org/10.1016/S0049-0172(98)80039-5).
- [3] R.A. Agha, T. Franchi, C. Sohrabi, G. Mathew, A. Kerwan, A. Thoma, A.J. Beamish, A. Noureldin, A. Rao, B. Vasudevan, B. Challacombe, B. Perakath, B. Kirshtein, B. Eksler, C.S. Pramesh, D.M. Laskin, D. Machado-Aranda, D. Miguel, D. Pagano, F. H. Millham, G. Roy, H. Kadioglu, L.J. Nixon, I. Mukhejee, J.A. McCaul, J. Chi-Yong Ngu, J. Albrecht, J.G. Rivas, K. Raveendran, L. Derbyshire, M.H. Ather, M. A. Thorat, M. Valmasoni, M. Bashashati, M. Chalkoo, N.Z. Teo, N. Raison, O. J. Muensterer, P.J. Bradley, P. Goel, P.S. Pai, R.Y. Afifi, R.D. Rosin, R. Coppola, R. Klappenbach, R. Wynn, R.L. De Wilde, S. Surani, S. Giordano, S. Massarut, S. G. Raja, S. Basu, S.A. Enam, T.G. Manning, T. Cross, V.K. Karanth, V. Kasivisvanathan, Z. Mei, S.C.A.R.E. The, Guideline: updating consensus surgical CAse REport (SCARE) guidelines, *Int. J. Surg.* 84 (2020) 226–230, <https://doi.org/10.1016/j.IJSU.2020.10.034>.
- [4] R. Kumar, Myasthenia gravis and thymic neoplasms: a brief review, *World J. Clin. Cases.* 3 (2015) 980, <https://doi.org/10.12998/WJCC.V3.I12.980>.
- [5] S. Virameteekul, S. Charoensri, K. Sawanyawisuth, S. Tiamkao, Concurrence of myasthenia gravis and thyroid disorders: a retrospective database study, *J. ASEAN Fed. Endocr. Soc.* 34 (2019) 153–157, <https://doi.org/10.15605/jafes.034.02.05>.
- [6] D.B. Drachman, Myasthenia gravis, *N. Engl. J. Med.* 330 (1994) 1797–1810, <https://doi.org/10.1056/NEJM199406233302507>.
- [7] F. Romi, Thymoma in myasthenia gravis: from diagnosis to treatment, *Autoimmune Dis.* 2011 (2011), <https://doi.org/10.4061/2011/474512>.
- [8] Myasthenia gravis Associated With Thymoma and Toxic Multinodular Goiter. A Case Report - PubMed, (n.d.). <https://pubmed.ncbi.nlm.nih.gov/23077950/> (accessed April 16, 2022).
- [9] A. Xie, R. Tjahjono, K. Phan, T.D. Yan, Video-assisted thoracoscopic surgery versus open thymectomy for thymoma: a systematic review, *Ann. Cardiothorac. Surg.* 4 (2015) 495, <https://doi.org/10.3978/j.issn.2225-319x.2015.08.01>.
- [10] S. Tomaszek, D.A. Wigle, S. Keshavjee, S. Fischer, Thymomas: review of current clinical practice, *Ann. Thorac. Surg.* 87 (2009) 1973–1980, <https://doi.org/10.1016/j.ATHORACSUR.2008.12.095>.
- [11] A. Pennathur, I. Qureshi, M.J. Schuchert, R. Dhupar, P.F. Ferson, W.E. Gooding, N. A. Christie, S. Gilbert, M. Shende, O. Awais, J.S. Greenberger, R.J. Landreneau, J. D. Luketich, Comparison of surgical techniques for early-stage thymoma: feasibility of minimally invasive thymectomy and comparison with open resection, *J. Thorac. Cardiovasc. Surg.* 141 (2011) 694–701, <https://doi.org/10.1016/j.JTCVS.2010.09.003>.
- [12] T.J. Liu, M.W. Lin, M.S. Hsieh, M.W. Kao, K.C. Chen, C.C. Chang, S.W. Kuo, P. M. Huang, H.H. Hsu, J.S. Chen, H.S. Lai, J.M. Lee, Video-assisted thoracoscopic surgical thymectomy to treat early thymoma: a comparison with the conventional transsternal approach, *Ann. Surg. Oncol.* 211 (21) (2013) 322–328, <https://doi.org/10.1245/S10434-013-3228-7>, 2013.
- [13] W.S. Lee, D.S. Heo, Y.J. Bang, K.S. Lee, J.S. Ahn, C.W. Jung, S.K. Han, S.W. Sung, J. H. Kim, Y.S. Shim, C.I. Park, N.K. Kim, Prognostic factors of patients with thymoma, *Korean J. Intern. Med.* 11 (1996) 40, <https://doi.org/10.3904/KJIM.1996.11.1.40>.
- [14] Z. Zhang, Y. Cui, R. Jia, L. Xue, H. Liang, Myasthenia gravis in patients with thymoma affects survival rate following extended thymectomy, *Oncol. Lett.* 11 (2016) 4177, <https://doi.org/10.3892/OL.2016.4528>.