

See discussions, stats, and author profiles for this publication at:
<https://www.researchgate.net/publication/276112981>

First time isolation of *Pseudomonas argentinensis* from human skin infection

Article · June 2014

DOI: 10.5799/ahinjs.02.2014.02.0133

CITATION

1

READS

5

1 author:



Sameer Barghouthi

Al-Quds University

21 PUBLICATIONS 267 CITATIONS

SEE PROFILE

CASE REPORT

First time isolation of *Pseudomonas argentinensis* from human skin infection

Sameer A. Barghouthi, Khalid Younis

Associate Professor of Microbiology, Department of Medical laboratory Sciences, Faculty of Health Profession, Al-Quds University, Jerusalem, Palestine

ABSTRACT

This reported the first isolation of *Pseudomonas argentinensis* from a human infection, since the discovery of *P. argentinensis* in 2005. A Palestinian 63-year male practicing gardening on sunny days with exposed arms and legs had experienced recurrent skin infections of forearms and legs. The skin infection progressed from small itchy red rash into fluid-filled vesicles within three days. One type of bacteria was recovered from culture samples of these vesicles. The infection was treated successfully with 2% fucidine. Using the Universal Method, the isolate (labeled as QUBC88) was identified as *Pseudomonas argentinensis*. The patient's son had suffered a similar skin infection while gardening in a different continent. The inability of the isolate QUBC88 to grow at 37°C may explain its inability to cause systemic infection. Future skin infections of the patients will be followed up to determine if the infectious agent is the same, related, or not related to *P. argentinensis*. *J Microbiol Infect Dis* 2014;4(2): 78-83

Key words: *Pseudomonas argentinensis*, MacConkey Blood Agar, Bacterial Identification, Skin infection, Fucidin.

İnsan cilt enfeksiyonundan ilk defa izole edilen *Pseudomonas argentinensis* olgusu

ÖZET

Bu 2005 yılında *Pseudomonas argentinensis*'in tanımlanmasından sonra insan kaynaklı tekrarlayan cilt enfeksiyonundan izole edilen ilk *P. argentinensis* olgusu bildirimidir. Filistinli 63 yaşındaki erkek bir hastada güneşli günlerde bahçede çalışırken ön kollarda ve bacaklarda tekrarlayan cilt enfeksiyonları gelişti. Üç gün içinde, cilt enfeksiyonu küçük kaşıntılı kırmızı raş lezyonlardan içi sıvı dolu veziküllere dönüştü. Bu veziküllerden alınan kültürde bir tip bakteri izole edildi. Bu lezyonlar %2 fusidin ile düzeldi. Üniversal Metot kullanılarak izolat (QUBC88 olarak etiketlendi) *Pseudomonas argentinensis* olarak belirlendi. Hastanın başka bir kıtada yaşayan oğlunda da bahçede çalışırken benzer cilt lezyonları gelişti. İzolat QUBC88'in 37°C'de üreyememesi sistemik enfeksiyon oluşturmama nedenini açıklayabilir. Hastalarda daha sonra gelişecek cilt enfeksiyonları izole edilecek mikroorganizmanın yanı sıra bakteri ya da *P. argentinensis* ile bağlantılı olup olmadığını belirlemek üzere takip edilecektir

Anahtar kelimeler: *Pseudomonas argentinensis*, MacConkey Kanlı Agar, Bakteriyel Tanımlama, Cilt Enfeksiyonu, Fucidin krem

CASE PRESENTATION

The co-author K. Younis (63 years old Palestinian male) working in his garden (Ateel, Palestine) observed a recurrent skin infection on his exposed legs and arms (Figure 1) that appeared as small itchy red spots within 24-48 h after gardening. Then, the spots had developed into clear vesicles (Figure 2). The patient had suffered another attack that was treated topically with 2% fucidin ointment; recovery was evident after 5-6 days of treatment (Figure 3).

After several months, a third time infection was recorded. All episodes were successfully treated with 2% fucidin ointment which relieved the itching as well. Younis's elder son MKY had suffered a similar skin infection while gardening in a different continent (Figure 4). The infection was local, not systemic nor pyrogenic; patients did not suffer any fever. Father and son are normal healthy males with no history of immune deficiency or underlying ailment. KY had avoided re-infection by wearing proper clothing to cover arms and legs.

Correspondence: Sameer A. Barghouthi, P.O.Box 3994, Al-Bierih, West Bank, Palestine
Email: bargsam@yahoo.com

Received: 07.11.2013, Accepted: 12.02.2014

Copyright © Journal of Microbiology and Infectious Diseases 2014, All rights reserved

Since the infection was treatable (within 6 days) with 2% fucidic acid ointment, it was assumed that the pathogen is likely to be a bacterial agent. Attempts to culture bacteria from 3-day old vesicles had failed once; possibly due to fucidic acid treatment prior to sample collection. Culture was obtained from a later infection (Figure 2); the patient presented with fresh infection (~70h after gardening) before antibiotic treatment. A well isolated vesicle was selected, disinfected with 70% ethanol, after air drying the vesicle was extracted with a sterile tuberculin needle/syringe in the Departmental Research Laboratory, the skin area was disinfected again after extraction. The extracted fluid (~3 µl) was streaked on duplicate Sheep Blood Agar and duplicate McSBA plates (McSBA was developed by S. A. Barghouthi; prepared by adding pre-warmed fresh defibrinated sheep blood 5-7% to MacConkey agar at 45°C). One plate each of SBA and McSBA was incubated aerobically; a duplicate set was incubated in a candle jar at 35.5°C.

One isolate (QUBC 88) was obtained only from both aerobic agar plates. QUBC 88 was a Gram negative bacillus that could grow aerobically but not microaerophilically (Figure 5). Growth did not occur at 36.9°C nor at 41°C on MacConkey and was poor at 35.5°C, the bacterium grew well at 30-33°C on MacConkey and Nutrient Agar media; it was strict aerobic, oxidase positive, and hydrolyzed L-arginine and gelatin. API 20NE system revealed that QUBC 88 differed from published *P. aeruginosa* ATCC 287853 profile.¹ QUBC 88 reduced both nitrate and nitrite, and showed no indole production, it was able to assimilate D-glucose, L-arabinose, D-mannose, D-mannitol, n-acetylglucosamine, gluconate, capronic acid, D-malate, and citrate. Unlike *P. aeruginosa*, it hydrolyzed esculin and assimilated L-arabinose and D-mannitol, otherwise both had similar API 20 NE reactions (Table 1). QUBC 88 was unable to grow at temperatures ≥ 37°C whereas *P. aeruginosa* grows at 43°C.²

Table 1. API 20NE results of QUBC 88 compared with published *P. aeruginosa*¹

API 20NE	NO3	TRP	GLU	ADH	URE	ESC	GEL	PNG	GLU	ARA	MNE	MAN	NAG	MAL	GNT	CAP	ADI	MLT	CIT	PAC	OX
QUBC 88	+/+	I	I	+	+	+	+	I	+	+	+	+	+	I	+	+	+	+	+	I	+
<i>P. aeruginosa</i>	+	I	I	>	>	I	+	I	+	I	I	+	+	I	+	+	+	+	+	I	+

The nucleotide sequence of DNA amplicon (~530bp) of the 16S gene of QUBC 88 was obtained using the Universal Method.³ BLAST analysis against available bacterial sequences revealed a close similarity to *Pseudomonas argentinensis*.⁴ Three *Pseudomonas* 16S sequences including *P. argentinensis* which most closely matched with isolate QUBC 88 were aligned (Figure 6) and a phylogenetic tree (Figure 7) was constructed using Clustalw multiple sequence alignment tool.⁵ The results showed better alignment between QUBC 88 and *P. argentinensis* as reflected by the rooted phylogenetic tree (Figures 6, 7). The tree indicated that *P. aeruginosa* and *P. fluorescens* to be less similar to QUBC 88.

Antibiotic profiling was carried out using the disc diffusion method on Mueller-Hinton agar.⁶ Interpretation of breakpoints and susceptibility were based on published literature for *Pseudomonas* spp. Table 2 summarizes the results.⁶⁻¹⁰

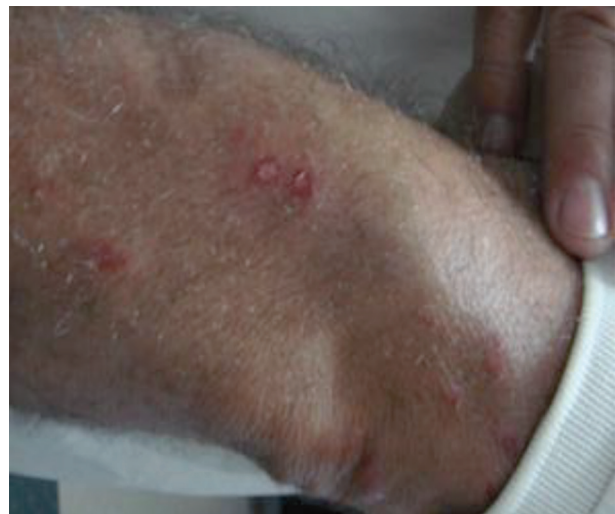

Figure 1. General Features of Infection. February 2009, KY Forearm infection (5 days after gardening) (Ateel, Palestine).

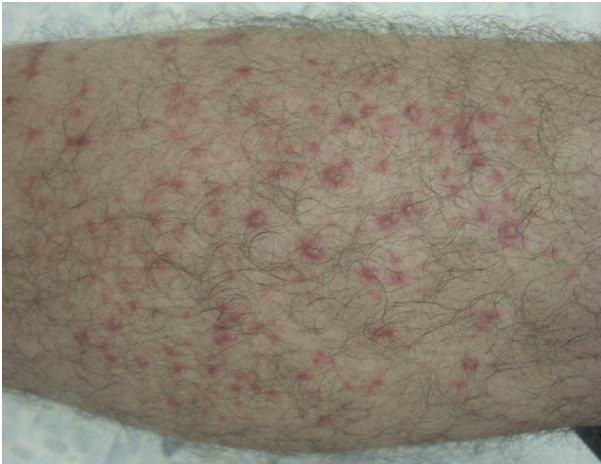


Figure 2. Early stages of infection. Different stages of acnes ranging from small red flat spots to mature vesicular acnes. 2-3 Days post gardening (KY; Oct 2012).

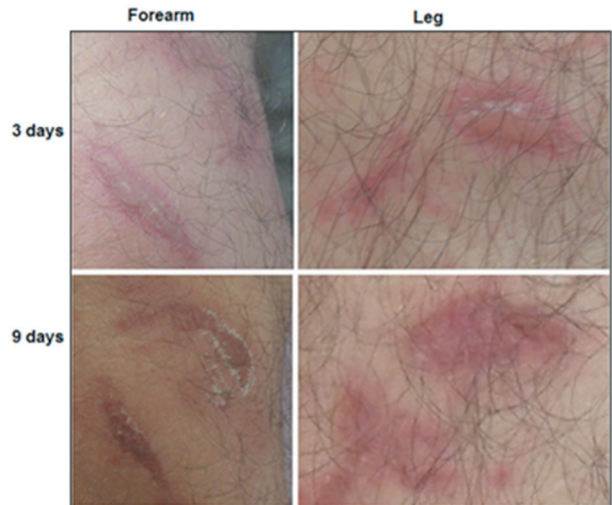


Figure 3. KY. After 3 and 9 days of treatment (post infection, or days 4 and 10 post exposure) with 2% fucidin ointment. Advanced stage of infection showing filled vesicle with clear fluid (4 day post exposure) which then become crusted and covered with scabs (10th day post exposure). The same areas of forearm and leg were photographed after 3 or 9 days of infection (12 M pixels; Casio, Exilim, EX-Z1200).

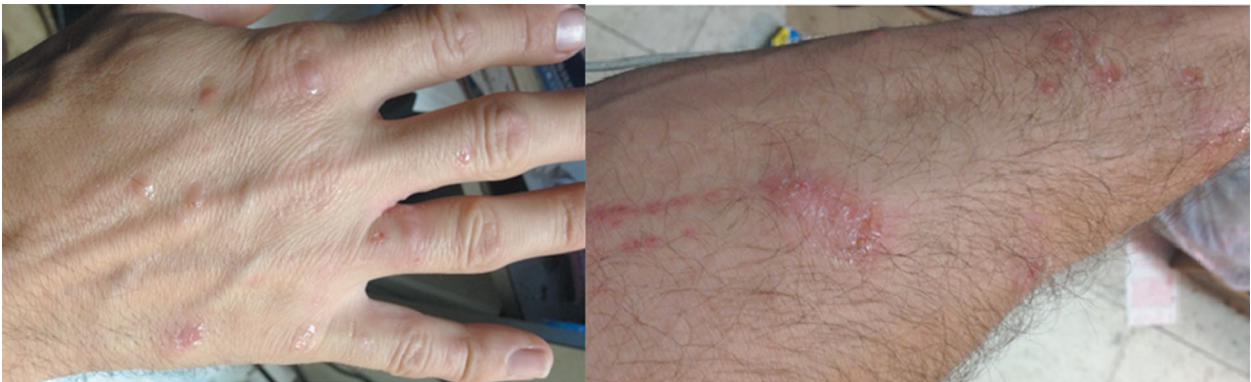

Figure 4. A similar infection shared by KY's Son MKY (38 years) while working in his garden in Louisiana, USA. MKY was successfully treated for allergy and with 2% fucidin ointment (within 6 days).

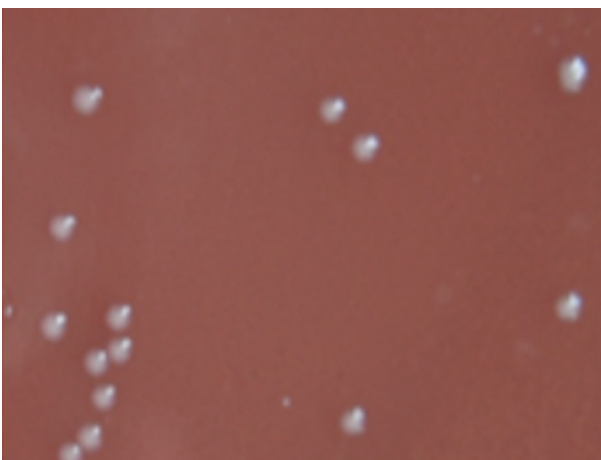


Figure 5. Primary Colonies on aerobic McSBA plate. These colonies were obtained directly from the clinical sample, showing a single type of bacterial white raised entire medium size colonies observed after overnight aerobic incubation.

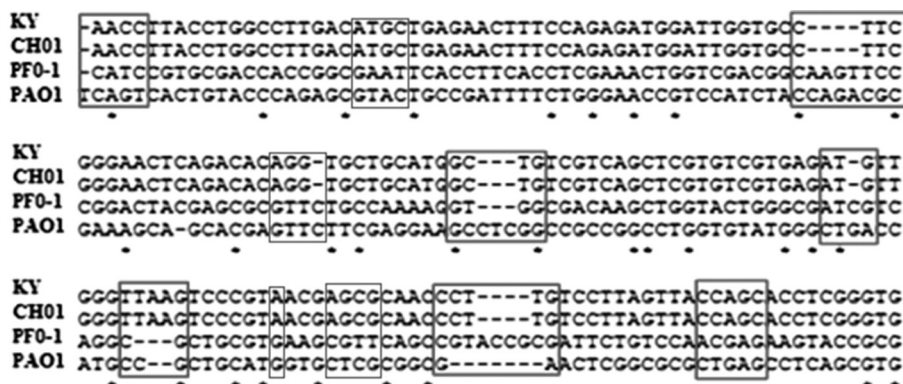


Figure 6. A part of the aligned DNA sequence showing identity between KY patient's isolate QUBC 88 and *P. argentinensis* CH01 while diverging from both *P. aeruginosa* PA1 and *P. fluorescens* PF0-1 as exemplified by boxed sequences. Prepared with online Clustalw multiple sequence alignment tool.⁵

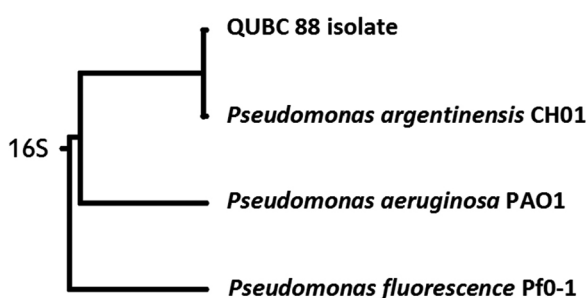


Figure 7. Rooted phylogenetic tree with branched length (UPGMA). 16S sequences of 3 known *Pseudomonas* spp. and isolate QUBC 88 from patient (KY), prepared based on alignments shown in figure 6.⁵

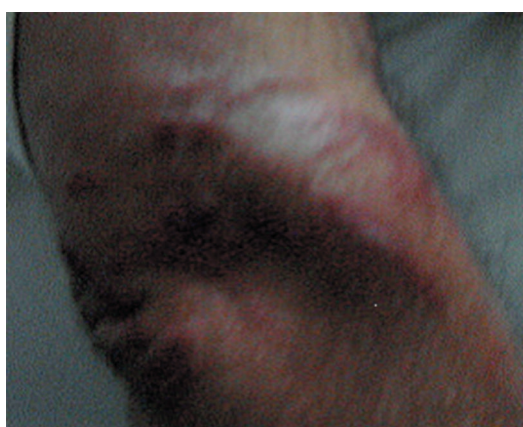

Figure 8. KY, Scratching can spread the infection. Scorching areas showing large contiguous areas of infection.

Table 2. Disc diffusion showing the isolate to be resistant to a large number of compounds, it is sensitive to fluoroquinolones based on published data by EUCAST.^{7,8,9}

Antimicrobial agent Family: Antibiotic (disc µg)	Zone of inhibition mm	Breakpoint* for <i>Pseudomonas</i> spp.	Effect
Fluoroquinolones: Moxifloxacin (MXF5)	32	17-25	Sensitive
Fluoroquinolones: Ofloxacin (OFX5)	32	17-21	Sensitive
Fluoroquinolones: Levofloxacin (LEV5)	36	13-18*	Sensitive
Fluoroquinolones: Ciprofloxacin (CIP5)	36	R [§] < 22-25 > S	Sensitive
Cephalosporin III : Ceftriaxone CRO30	0.0	R < 30 mm	Resistant ^o
Cephalosporin III : Ceftazidime CAZ30	22	S > 16 mm < R	Sensitive
Oxytetracyclin T 30	20	S ≥ 19	Sensitive

*Breakpoints published for *Pseudomonas* spp. (12-14). Resistant (R) or sensitive (S) to antibiotic.

^oOther antibiotic discs showing no zone of inhibition were: Azithromycin AZM15; Trimethoprim Tmp5, Bacitracin B10, Cefuroxime CXM30; Amoxicillin AX25; Cloxacillin CX1; Erythromycin E15; Methicillin MET5; Cephalixin CL30.

[§] Other zones of inhibition were recorded: Clarithromycin CLR15 (8 mm), Nalidixic acid Na30 (16mm), Trimethoprim/sulfamethoxazole SXT25 (7 mm), and Rifampicin RA15 (15 mm).

DISCUSSION

Recently, *Pseudomonas argentinensis* was isolated and described from a soil sample, Cordoba, Argentina.¹¹ Since then, the bacterium was isolated from mouth and vaginal mucous membranes of cats.¹² To the best of our knowledge, the bacterium has not been reported to cause any infections in human; this is the first report of isolating *P. argentinensis* from a human; a skin infection. Similar skin infections may be caused by *Pseudomonas aeruginosa*; an infection known as "Hot Tub Folliculitis".¹³ Other bacteria such as the Gram positive microaerophilic *Propionibacterium* spp. can cause similar skin infections but responds slowly or poorly to treatment with 2% fucidic acid.^{14,15} *Acinetobacter lwoffii* may also cause skin rashes that may be confused for allergic reactions.¹⁶

In this reported case, the local skin infection occurred shortly after exposure to the bacterium; no other predisposing factors could be identified or suspected. The infection of exposed skin and evolution into vesicles suggested that the bacterium was an invasive bacterium. However, its confinement to contacted areas of the skin and inability to produce systemic infections suggested that host defenses including body temperature of 37°C were sufficient to prevent the spreading of the infection to other organs. The recurrent skin infection observed in plates (Figures 1-4, 8) may have been caused by the same bacterial pathogen or a related pathogen that took advantages of similar opportunities.

The new McSBA was able to inhibit several tested Gram positive bacteria while allowing *P. argentinensis* to grow, the medium supported the growth of *Campylobacter jejuni* ATCC 29428 when incubated microaerophilically, the medium is being tested for its ability to support the growth of fastidious Gram negative bacteria such as *Helicobacter*, *Neisseria*, *Haemophilus*, and others.

Itching induced patients to scratch infected areas causing infection to spread (Figures 4,8). Host factor(s) and bacterial virulence factors involved in this infection cannot be determined from the present study. However, it can be assumed that host susceptibility and specific bacterial factors are required to generate this skin infection. The rarity of *P. argentinensis* human skin infections suggests a unique set of factors involved in pathogenesis.

The localization of infection and absence of fever, bacteremia, and systemic infection were observed. The bacterium apparently cannot infect the majority of the population since this case is rarely

observed among farmers, gardeners, and workers exposed to contaminated soils. Infection can be avoided by properly covering skin and avoidance of skin contact with contaminated sources.

Although father and son are normal healthy males with no history of immune deficiency or any known underlying deficiency or disease, and they represent two different age groups (Father is 63 and son is 38), they possibly share a predisposition to such infections. Three pieces of evidence can be identified; First, the recurrence (episodes of 2009, 2011, and 2012) of skin infections that may or may not have been caused by the same pathogen. Second; The son MKY was infected with similar skin lesions after gardening in his garden in the USA (Figure 4), MKY responded to the same treatment with 2% fucidic acid within similar time frame as his father; unlike the poor effect of 2% fucidic acid reported for the treatment of acnes caused by *Propionibacterium acnes*.¹⁴ Third, most individuals working in the fields and gardens rarely suffer similar infections. Our preliminary investigation has indicated that a small number of individuals who are exposed to soils may suffer similar skin infections that is not well known, but some refer to it by the local name "Dannam". A plan is currently underway to meet such individuals (Summer time) and study the cases of "Dannam"; if it turns out to be *P. argentinensis*, a related bacterium, or different bacterium/bacteria, then different strategies can be adopted to answer the many questions arising from Dannam and recurrent infection studies; Is the bacterium an opportunistic pathogen? Is it dose dependent? Is the host particularly susceptible to infection? What is the common predisposing factor among patients if there is one?

Similar skin infections may be caused by *Pseudomonas aeruginosa*.¹³ Other bacterial agents that may cause similar skin infections are the Gram positive bacteria, including *Propionibacterium acnes* and *P. granulosum*, these do not respond well to treatment with 2% fucidic acid.^{14,15,16} Viral rashes, warts, and skin infections are well documented; these are usually systemic, age dependent, and mostly pyrogenic.

In conclusion, rare cases and opportunistic infections represent excellent indicators, tools, and opportunities for understanding bacterial virulence and the specific host defenses. In-depth analysis of these infections shall reveal new bacterial virulence factors and host defenses, such revelations are important components of our combat against diseases. Further investigations of this case and

other rare cases are strongly commended if we are to advance our knowledge and health care system.

Patient Consent

Written informed consents were obtained from the patients for publication of this case report and Plates (figures) with figures.

Competing interests

The presented work was funded by the authors; hence, the authors declare that they have no competing interests.

Acknowledgment: The authors would like to thank Mr. Marwan K. Younis for participating in this case report and Al-Quds University for their continuous unwavering support of research.

REFERENCES

1. API 20NE: Identification system for non-fastidious, non-enteric Gram-negative rods. <http://www.netropica.org/bacteriologia/Api20NE%281%29.pdf>. Accessed 6 November 2013.
2. Rolfe B, Holloway BW. Alterations in host specificity of bacterial deoxyribonucleic acid after an increase in growth temperature of *Pseudomonas aeruginosa*. *J Bacteriol* 1966;92:43-48.
3. Barghouthi SA. A Universal Method for the Identification of Bacteria Based on General PCR Primers. *Ind J Microbio* 2011;51:430-444.
4. BLAST. http://www.ncbi.nlm.nih.gov/blast/Blast.cgi?PROGRAM=blastn,BLAST_PROGRAMS=megaBlast,PAGE_TYPE=BlastSearch,SHOW_DEFAULTS=on,LINK_LOC=blasthome. Accessed 6 November 2013.
5. Clustalw. <http://www.genome.jp/tools/clustalw/>. Accessed 6 Nov, 2013.
6. Hudzicki J. <http://www.microbelibrary.org/component/resource/laboratory-test/3189-kirby-bauer-disk-diffusion-susceptibility-test-protocol>. Accessed 6 Nov 2013.
7. European Committee on Antimicrobial Susceptibility Testing (EUCAST). Breakpoint tables for interpretation of MICs and zone diameters Version 3.1. http://www.eucast.org/fileadmin/src/media/PDFs/EUCAST_files/Breakpoint_tables/Breakpoint_table_v_3.1.pdf. Accessed 6 November 2013.
8. Tripathi P, Banerjee G, Saxena S, et al. Antibiotic resistance pattern of *Pseudomonas aeruginosa* isolated from patients of lower respiratory tract infection. *Afr J Microb Res* 2011;5:2955-2959.
9. El-Hady MA, Samy AA. Molecular Typing of *Pseudomonas* Species Isolated from Some Cultured Fishes in Egypt. *Glob Vet* 2011;7:576-580.
10. Levy PY, Fenollar F, Stein A, et al. *Propionibacterium acnes* postoperative shoulder arthritis: an emerging clinical entity. *Clin Infect Dis* 2008;46:1884-1886.
11. Peix A, Berge O, Rivas R, et al. *Pseudomonas argentinensis* sp. nov., a novel yellow pigment-producing bacterial species, isolated from rhizospheric soil in Cordoba, Argentina. *Int J Syst Evol Microbiol* 2005;55:1107-1112.
12. Hariharan H, Matthew V, Fountain J, et al. Aerobic bacteria from mucous membranes, ear canals, and skin wounds of feral cats in Grenada, and the antimicrobial drug susceptibility of major isolates. *Comp Immunol Microbiol Infect Dis* 2011;34:129-134.
13. Hot tub rash. <http://www.skindsight.com/adult/pseudomonas-FolliculitisHotTubFolliculitis.htm>. Accessed 6 November 2013.
14. Sommkar S, Bojar R, Cunliffe WJ, et al. Investigation of the mechanism of action of 2% fusidic acid lotion in the treatment of acne vulgaris. *Clin Exper Derm* 1997;22:211-215.
15. Nayak N, Verma L, Satpathy G, Venkatesh P. *Propionibacterium acnes* endophthalmitis. *J Clin Diag Res* 2007;3:155-158.
16. Barghouthi SA, Hammad G, Kurdi M. *Acinetobacter iwoffii* induced cellulitis with allergy-like symptoms. *Internet J Microbiol* 2012;10:12-17.