

# Journal of Gastroenterology and Hepatology Research

Online Submissions: <http://www.ghrnet.org/index./joghr/>  
doi: 10.17554/j.issn.2224-3992.2019.08.814

Journal of GHR 2019 April 21; 8(2): 2841-2852  
ISSN 2224-3992 (print) ISSN 2224-6509 (online)

REVIEW

## Current Status Regarding Tumour Progression, Surveillance, Diagnosis, Staging, and Treatment Of HCC: A Literature Review

Muntaser S. Ahmad, Nursakinah Suardi, Ahmad Shukri, Hjouj Mohammad, Ammar A. Oglat, Bassam M. Abunahel, Aboubakr M.H Mohamed, Osama Makhamrah

Muntaser S. Ahmad, PhD candidate, Department of Medical Physics and Radiation Science, School of Physics, Universiti Sains Malaysia, 11800 Penang, Malaysia

Nursakinah Suardi, PhD lecturer, Department of Medical Physics and Radiation Science, School of Physics, Universiti Sains Malaysia, 11800 Penang, Malaysia

Ahmad Shukri, Prof. Department of Medical Physics and Radiation Science, School of Physics, Universiti Sains Malaysia, 11800 Penang, Malaysia

Hjouj Mohammad, Associate Professor, Medical Imaging Department, Faculty of Health Professions, Al-Quds University, Abu Deis - Main Campus, Jerusalem, Palestine

Ammar A. Oglat, PhD candidate, Department of Medical Physics and Radiation Science, School of Physics, Universiti Sains Malaysia, 11800 Penang, Malaysia

Bassam M. Abunahel, Master candidate, Department of Medical Physics and Radiation Science, School of Physics, Universiti Sains Malaysia, 11800 Penang, Malaysia

Aboubakr M.H Mohamed, Master candidate, Department of Medical Physics and Radiation Science, School of Physics, Universiti Sains Malaysia, 11800 Penang, Malaysia

Osama Makhamrah, Master candidate, Medical Imaging Department, Faculty of Health Professions, Al-Quds University, Abu Deis - Main Campus, Jerusalem, Palestine

**Conflict-of-interest statement:** The authors declare that there is no conflict of interest regarding the publication of this paper.

**Open-Access:** This article is an open-access article which was selected by an in-house editor and fully peer-reviewed by external reviewers. It is distributed in accordance with the Creative Commons Attribution Non Commercial (CC BY-NC 4.0) license, which permits others to distribute, remix, adapt, build upon this work non-commercially, and license their derivative works on different terms, provided the original work is properly cited and the use is non-commercial. See: <http://creativecommons.org/licenses/by-nc/4.0/>

**Correspondence to:** Muntaser S. Ahmad, PhD candidate, Department of Medical Physics and Radiation Science, School of Phys-

ics, Universiti Sains Malaysia, 11800 Penang, Malaysia.

Email: [wmuntaser@gmail.com](mailto:wmuntaser@gmail.com)

Telephone: +923408362337

Received: January 19, 2019

Revised: Marh 13, 2019

Accepted: Marh 17, 2019

Published online: April 21, 2019

### ABSTRACT

Hepatocellular carcinoma (HCC) is the most common primary malignant tumour of the liver, and is globally considered to be a major causes of cancer-associated mortality. The early diagnosis of HCC improves overall survival through the application of suitable treatment options. This article presents some of the techniques for the surveillance of HCC like ultrasonography and the use of tumour biomarkers such as  $\alpha$ -fetoprotein (AFP), DesGamma-Carboxy Prothrombin (DCP) and others. Included in the discussion will be diagnostic methods like computed tomography (CT), magnetic resonance imaging (MRI), contrast enhancement ultrasound (CEUS), and fluorodeoxyglucose positron emission tomography hybrid with computed tomography (FDG PET/CT). Current molecular pathogenesis related to HCC and the molecular steps that determine the transition from benign to malignancy are also analysed. The HCC stages which depends on the Barcelona Clinic Liver Cancer (BCLC) algorithm are also discussed. Finally, this review article discusses the present therapeutic and treatment options for HCC such as resection, transplantation, or ablation used to treat early stage cancer. Also included will be trans-arterial chemoembolization (TACE) and Sorafenib for patients with intermediate and advanced-stage cancer, respectively.

**Key words:** Hepatocellular carcinoma; Barcelona Clinic Liver Cancer; trans-arterial chemoembolization; Sorafenib

© 2019 The Author(s). Published by ACT Publishing Group Ltd. All rights reserved.

Ahmad MS, Suardi N, Shukri A, Mohammad H, Oglat AA, Abunahel BM, Mohamed AMH, Makhmrah O. Current Status Regarding the Tumour Progression, Surveillance, Diagnosis, Staging, and Treatment Of HCC: A Literature Review. *Journal of Gastroenterology and Hepatology Research* 2019; **8(2)**: 2841-2852 Available from: URL: <http://www.ghrnet.org/index.php/joghr/article/view/2504>

## INTRODUCTION

Hepatocellular carcinoma (HCC) is considered as primary carcinoma in the liver, and the third vital carcinoma in the world after lung cancer and colorectal cancer. It was described as the fifth and seventh most common cancer in men and women, respectively<sup>[1]</sup> HCC global distribution differs depending on the country, for example, African or Asian people, the HCC is considered as the most morbidity cancer into these countries. There are different risk-factors which increases the risk of HCC including hepatic cirrhosis, chronic inflammations such as Hepatitis B- (HBV), Hepatitis C-virus (HCV), alcohol consumption, aflatoxin exposure, non-alcoholic fatty liver disease (NAFLD) and autoimmunity cases<sup>[1]</sup>.

The microenvironment is complex system considered to contain many components such as stromal cells, extracellular matrix (ECM) components (proteoglycans, collagens), hepatic stellate cells (HSC), fibroblasts, myofibroblasts and soluble factors, non-cellular components (such as cytokines and growth factors). The microenvironment is an essential media for epithelial cell transformation, the cell polarity and cell proliferation controlled by this transformation<sup>[2]</sup> HCC and ICC are still deadly cancers worldwide waiting for innovative therapeutic options. Growing evidence from the literature highlight the critical role of the tumor cell microenvironment in the pathogenesis of cancer diseases. Thus, targeting the microenvironment, particularly the crosstalk between tumor cells and stromal cells, has emerged as a promising therapeutic strategy. This strategy would be particularly relevant for liver cancers which frequently develop in a setting of chronic inflammation and microenvironment remodeling associated with hepatic fibrosis and cirrhosis, such processes in which hepatic stellate cells (HSC). The wrong change in the micro-environment leads to the formation of cancer by changing the distribution of molecular biology, histopathology, biochemistry, and genes deformation.

HCC propagate and starts to be metastasis in different organs of the body such as lungs (55%), bone (28%), adrenal glands (11%), lymph nodes (53%), and brain (2%). It is considered very rare to affect other organs like spleen, duodenum, esophagus, or seminal vesicles. In the present work, the risk factors that leads to HCC, tumor progression, diagnosis, surveillance, staging, and treatments in HCC are summarized.

## EPIDEMIOLOGY, ETIOLOGY AND RISK FACTORS

The rate of incidence of HCC increases with age and it reaches a peak at 65 years in European countries, while for populations in East Asia and Africa the age of incidence of HCC is much lower. HCC is uncommon in patients under 40 years old, and increasing with patients aged over 65 years, with the highest probability in patients aged over 75 years.

The HCC malignant progression is related to genetic, lifestyle and environmental factors<sup>[3]</sup> which is associated with progression to cirrhosis and is rapidly becoming the leading indication for liver transplantation. Sarcopenia is defined as a progressive and generalized loss of skeletal muscle mass, strength and function. It is seen in up

to 60% of patients with end-stage liver disease and portends a poor prognosis. Recent studies have shown sarcopenia as a novel risk factor for developing NAFLD. Pathophysiological mechanisms relating sarcopenia and NASH may include insulin resistance (IR). There are many main risk-factors for HCC and other hepatocarcinogenesis including hepatic cirrhosis, chronic inflammations such as HBV, HCV, alcohol consumption, cigarette smoking, aflatoxin exposure, NAFLD, and autoimmune diseases. HBV patients, unlike HCV patients it can immediately develop HCC without going through cirrhosis first. At the same time, NAFLD increases the HCC probability and happens mainly in patients with metabolic syndrome and obesity<sup>[3]</sup> which is associated with progression to cirrhosis and is rapidly becoming the leading indication for liver transplantation. Sarcopenia is defined as a progressive and generalized loss of skeletal muscle mass, strength and function. It is seen in up to 60% of patients with end-stage liver disease and portends a poor prognosis. Recent studies have shown sarcopenia is a novel risk factor for developing NAFLD. Pathophysiological mechanisms relating sarcopenia and NASH may include insulin resistance (IR and type 2 diabetes<sup>[4]</sup> provided that all other etiologies of liver disease were ruled out, fatty liver was present on abdominal ultrasound and alcohol consumption was excluded. Also, the human immunodeficiency virus (HIV) is considered a co-risk factor for HCC development<sup>[5,6]</sup>.

## THE HCC PROGRESSION

The liver continuously repairs the damaged cells within it. If the liver cells are continually forced to repair itself, this raises the chances of genetic mistakes or mutation, which potentially leads to development of carcinogenesis.

In the hepatocytes, the connective tissue surrounding the hepatic cells contain different types of cells such as fibroblasts, endothelial cells, and macrophages. After the development of a tumor in the epithelial cell, the tumor cells spread within the surrounding cells and then penetrate the cells and contact the ECM. Thus, the tumor cells will produce the tumorigenesis factors like cytokines and growth factors such as transforming growth factor beta (TGF- $\beta$ ) and platelet-derived growth factor (PDGF). The PDGF stimulates the tumor proliferation associated fibroblasts while TGF- $\beta$  stimulates the synthesis of connective tissue. The activated fibroblasts which are produced by the different tumorigenesis secretions will produce some components which are related to the connective tissue such as collagen 1 and 3. Therefore, the TGF- $\beta$  stimulates to generate the matrix metalloproteinase 9 (MMP9) which are symbolized as scissors, and the latter would work on the digestion of connective tissue components such as collagen fibers<sup>[7]</sup>.

### 1. The role of hepatocyte growth factor in the development of HCC

Both PDGF and TGF- $\beta$  co-energize to activate the HSCs<sup>[8]</sup>. HSC works on the development of cancer cells. This occurs by producing the cytokines and growth factors to help the cell proliferation for cancer cells like hepatocyte growth factor (HGF) which is also known as scatter factor, and interleukin-6 (IL-6).

HGF binds to the cell membrane receptor of tumor cells activating MET which stimulates motility and invasive growth of HCC cells<sup>[9]</sup>. The epithelium experiences higher pressure whenever the density of the connective tissue matrix increases. The higher pressure may produce morphological changes like those seen in carcinomas. In this model, tumor associated fibroblasts produce collagen fibrils as a response to TGF- $\beta$ , with increasing collagen content and stiffness

of the connective tissue matrix, whereby the regular structure of the gland is lost.

When HGF connects to c-Met, which is considered one of the tyrosine kinase receptors, which are found in endothelial cells, hepatocytes, neurons, and epithelial cells which involve the epithelial-mesenchymal transition. However, HGF induces the c-Met to activate, and stimulate the signalling pathways such as signal transducer and activator of transcription, phosphoinositide 3-kinase (PI3K), mitogen activated protein kinase (MAPK), and nuclear factor kappa-B (NFκB). Thus, c-Met induces the proliferation, survival, invasiveness, mobilization, vascular endothelial growth (VEGF-A) expression which is released by tumor angiogenesis<sup>[10]</sup> and epithelial-mesenchymal transition<sup>[11]</sup>.

In addition, the HSC was noticed as a primary cell in tumorigenesis associated with the gut system. Therefore, the gut system works to stimulate the inflammatory and fibrogenic responses. Thus, the HSC activation will produce epiregulin which is used as a mitogenic factor for hepatocytes<sup>[9]</sup>. HSC is involved in tumor formation in late stages as in the early stages. It works to produce the factors that share to form the prometastatic microenvironment such as epithelial-mesenchymal cell transition (EMT) in which the epithelial cells lose their ability to stick between cells<sup>[7]</sup>. The HSC also helps to produce immune-regulatory cytokines such as monocyte chemoattractant protein 1 (MCP1), chemokine ligand 21(CCL21) and CCL 5, chemotaxis and activate inflammatory cells.

## 2. The role of diseases in the development of HCC

### 2.1. Liver cirrhosis

HCC is associated with other liver diseases that increase the risk of cancer development and grow in the liver such as liver cirrhosis. Where one-third of patients with liver cirrhosis develop their disease due to HCC. Liver cirrhosis is associated with other diseases such as alcoholic hepatitis, hereditary hemochromatosis, primary biliary cirrhosis, alpha-1 antitrypsin (A1AT, A1A, or AAT) deficiency, and others<sup>[12]</sup>.

### 2.2. Chronic Inflammations

The second most common risk factor that is linked with HCC are the different inflammations such as HBV and HCV. This is because it is involved in the pathogenesis of cancer. Both of these inflammations would be developed into chronic or long-lasting. In this case, the cells are at a higher risk because of the constant state of infection and immune cell attack leading to continuous damage and repair. HBV is particularly problematic because of how the virus replicates. HBV is a DNA virus that integrates into the hepatocyte's DNA, which is still not completely understood. It is thought to either directly disrupt the regulation of cell growth and replication leading to carcinoma or cause some indirect effect that later leads to unchecked cell growth and replication<sup>[13]</sup>. Recent studies have identified distinct surface markers of cancer stem cell (CSC). HCV acts on cell signalling pathways by inhibiting the tumor suppressor genes (P53) and suppresses the retinoblastoma protein, which increase the probability of carcinogenesis. Moreover, the HCV induces the TGF-β to activate the HSCs<sup>[5]</sup>.

In addition, the variety of inflammations represent a useful prognostic marker for HCC, including fibrinogen, inflammation based index (IBI), C-reactive protein (CRP), inflammation based score (IBS), Glasgow prognostic score (GPS), and neutrophil to lymphocyte ratio (NLR)<sup>[14]</sup>. NLR is a simple marker of inflammation, it provides a good indication of the patient's overall inflammatory status, also it has been used to predict tumor recurrence in HCC

patients after hepatic resection<sup>[15,16]</sup> hepatocellular carcinoma (HCC. NLR has been related with activate caspase-1, which induce to produce the interleukin-18 (IL-18) and interleukin-1β (IL-1β). The NLR also plays a key role in cell proliferation, survival and invasion. NLR is interested in NF-κB and MAPK for signalling pathways. Thus, NLRs share in progression of HCC<sup>[15,16]</sup>.

### 2.3. Aflatoxin B1 exposure

Another risk factor is Aflatoxin B1 exposure which is considered a highly toxic chemical produced by certain *Aspergillus* molds that can be found in specific food when they start to decay like grains, peanuts and vegetables. The Aflatoxin B1 is metabolized in the liver. Its epoxide can bind to liver cell DNA, resulting in DNA adducts. This interaction leads to mutations in the protein p53 (TP53) tumor suppressor gene. The p53 gene usually right functioning by stopping the formation of tumors by converting the cytochrome P450 into 8,9-exo-epoxide, thus the DNA damaging would not be happened, but if the mutation and dysfunction occurred, the tumor formation and carcinogenesis might follow<sup>[12]</sup>.

### 2.4. Hormone Distribution

The sex differences of androgenic hormones are considered as another risk factor. Testosterone accelerates hepato-carcinogenesis, while estrogen suppresses the development of liver cancer. Because of that, the HCC prevalence in males are higher than that of the female while the diagnosis related age in females is more than males<sup>[12]</sup>.

## 3. HCC Biomarkers

Biomarkers for HCC are associated with variations in metabolism, and genetic, epigenetic, and protein levels. Metabolic changes play an essential role in determining the different HCC stages. The differential metabolites such as glutamine, short/medium chain acylcarnitines, pro-inflammatory precursor arachidonic acid level, and cyclic adenosine increase the probability of HCC formation<sup>[18]</sup>.

### 3.1. RNA Biomarkers

The human genome consists of less than 2% of protein-coding genes. More than 90% of the genome is copied to non-coding RNA (ncRNA) such as microRNAs (miRNAs), which is related to potential disease biomarkers. The miRNAs are considered as small non-coding RNA molecules. They contain 22 nucleotides and regulates the expression of genes at the post-transcriptional level. The miRNAs can be confined found into a vesicle, especially an exosome of about 50-100 nm diameter and then excreted to the extracellular environment and transferred into recipient cells<sup>[19]</sup>. The cellular miRNAs regulate the different cell activities such as differentiation, apoptosis, proliferation and angiogenesis<sup>[20]</sup>.

The nucleus contains the miRNAs genes which are similar to the proteins. RNA polymerase II is responsible for transcribing DNA genes, which produces either a messenger or regulatory RNA. The hairpin loop structure of primary miRNA will become the final miRNAs by several steps of transcription process. The miRNAs are produced by cutting the RNA into the smaller precursors, via the microprocessor complex which is formed by protein DGCR8 getting associated with enzyme Drosha. After that, the miRNAs can be exported into the cytoplasm. Thus, the messenger RNA will be inactivated in multiple genes. Exportin-5 (XPO5) works as a transporter of the precursor miRNAs out of the nucleus through the nuclear pores. In the cytoplasm, the miRNAs can be recognized by a large RNA protein known as Dicer. The role of Dicer is to cleave the

miRNA into short double-stranded molecules, which binds with<sup>[21]</sup>. The release of one strand is occurred, while the strand which remains that known as the guide strand will interact with another protein to form the RNA that motivate a silencing complex RISC. The RISC complex prevents the ribosome subunit from translating into a protein, so the gene is silenced. The tumorigenesis development can happen in the interaction between non-coding RNAs (lncRNAs), mRNAs and miRNAs<sup>[1]</sup>.

### 3.2. Genetic level

At the genetic level, many mutated genes related to HCC such as ubiquitin conjugating enzyme E2 Q1(UBE2Q1), TP53, HOTTIP, telomerase reverse transcriptase (TERT), catenin beta 1 (CTNNB1), and myelocytomatosis (MYC) were discovered. MYC is considered as a regulator gene for the transcription factor that adjusts the expression of genes for different kinds of genes in the cancer features such as proliferation, survival, metabolism, and self-renewal. Thus, inactivation of MYC oncogene leads to tumor regression associated with differentiation, apoptosis, and proliferative arrest<sup>[20]</sup>. The gene encoding HOTTIP have also been shown to have a significant oncogenic role in HCC, by dysregulation of HOXA genes.

Hexokinase is one of the enzymes found only in HCC and not in healthy liver cells. There are five hexokinases encoded by different genes in the human cells. Hexokinase 2 (HK2) is found in cardiac and skeletal muscles, outer mitochondrial membrane and adipose tissues and are also found in cancer cells. The HK2 induces the HK4 or glucokinase (GCK), which is the main hexokinase in HCC<sup>[22]</sup>. Moreover, HK2 induces the glucose transporter 1 (GLUT-1) which induce p53, and the PI3K/AKT pathway<sup>[13]</sup>.

### 3.3. Epigenetic level

Epigenetic alterations, will occur through changes at the gene transcription level without changing the DNA sequence. Thus, the gene expression level would be altered. The characterized of the ncRNAs and the related with HCC were identified by using advanced sequencing technologies. The changing of the series of nucleotides between 26 to 32 in ncRNAs represents approximately half of HCC tumors cases. This change is linked directly to increased proliferation rate and leads to improvement in the tumorigenesis properties, and that happens through active AKT signaling. At the same time the abnormal regulation either via upregulation of miR-21, miR-34a, miR-221 and miR-222 or downregulation of miR-122a, miR-145, miR-199a and miR-223 leads to HCC.

MiR-122 is considered a negative regulator of pyruvate kinase isoenzyme M2 (PKM2). PKM2 represents as inhibitor of HCC aerobic glycolysis, *in vitro* cell proliferation, as well as *in vivo* tumour

growth and metastasis. Moreover, also the pyruvate kinase can be regulated by mineralocorticoid targeting miR-388-3p<sup>[13]</sup>. Figure 1 shows the composition and miRNAs in the HCC-derived exosome.

### 3.4. Protein level

As for proteins, the high-mobility group box protein 1 (HMGB1) is one of the nuclear DNA binding protein which binds to chromatin, and is found in eukaryotic cells. HMGB1 plays a vital role in HCC carcinogenesis invasiveness and progression. The nucleus and the cytosol secretes the HMGB1 into the ECM. When HMGB1 is combined with DNA, it interacts with the different kinds of transcription factors such as NF-κB, p53, and TATA-binding proteins. In the ECM, the HMGB1 links to many receptors such as glycation end products (RAGE), (TLR)-2, TLR-4, TLR-9, and activating renin-angiotensin system (RAS)-MAP kinase<sup>[23]</sup> high mobility group box 1 (HMGB1).

Forkhead box protein M1(FOXM1) is another protein which is found in HCC and which is encoded by the FOXM1 gene. FOXM1 is used as a biomarker for prediction of cancer at the early stages. It plays an important role in mitotic division, and also affects the S and G2/M phases by regulating the expression of G2/M specific genes such as cyclin B2, Plk1, CENPF, and Nek2. In addition of that, FOXM1 plays an essential role in chromosomal segregation maintenance<sup>[24]</sup>.

The control mechanism in the mitotic phase that ensures accurate chromosome segregation is the spindle assembly checkpoint (SAC), and any defect of SAC leads to tumorigenesis. Aurora kinase A (AURKA), is one of the mitotic serine/threonine kinases which plays a vital role in mitosis that is related to centrosome duplication and separation, maturation, and cytokinesis (function of cell proliferation). The dysregulation of AURKA leads to chromosomal instability and increases the probability of tumorigenesis such as HCC. AURKA promotes tumour proliferation, differentiation, metastasis, and induces chemo-sensitivity in HCC<sup>[25]</sup>.

There are other proteins associated with mitotic division such as Zwint proteins. Zwint is a complex-centromere protein component required for the SAC process; it is involved in kinetochore function (disc-shaped protein structure, found at the centromere of a chromatid) and growth of the cell. Zwint connects with Zw10 (another kinetochore protein) to regulate the interaction between Zw10 and other kinetochores. Moreover, Zwint is associated with chromosome-instability and found in many human malignancies and prognosis in primary tumors. Zwint depletion may reduce cell proliferation and HCC cell-cycle progression<sup>[26]</sup>. A centromere-complex component required for the mitotic spindle checkpoint, has been reported to be overexpressed in different human cancers, but it has not been studied in human HCC.

In addition, many hepatic progenitor cell (HPC) markers include Osteopontin, epithelial cell adhesion molecule (EpCAM), neural cell adhesion molecule (NCAM), cytokeratin 19 (CK19), Niemann-Pick C1-like 1 (NPC1L1), delta-like 1 homolog (DLK1), surface marker Vimentin, DNA repair pathway members and TGF-β/Sirtuin have been identified as a potential functional biomarkers of HCC<sup>[12]</sup>.

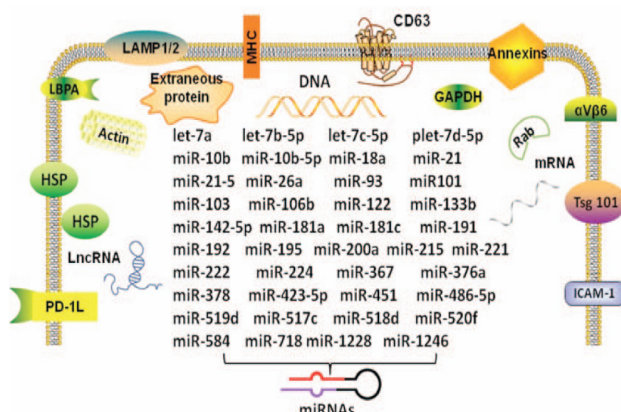


Figure 1 Composition and miRNAs in the HCC-derived exosome.

## DIAGNOSIS OF HCC

Non-invasive imaging is an important method to detect stages of HCC. The basic concept of HCC is to detect peculiar vascular perturbation, which occurs through hepatic carcinogenesis. The HCC detection is based on contrast enhancement in diagnostic modalities like CT and MRI. There are three phases enhancement

to visualize the lesions: late arterial phase, portovenous phase, and delayed phase.

The HCC has a typical hallmark of contrast enhancement because the nutrients of HCC are directly coming from the hepatic artery while the parenchymal cells derive oxygen and nutrients via the portal vein. Thus, the HCC has shown as a hyper-vascularity in the late arterial phase, while in the portovenous phase HCC behaves less bright because it contains blood free of contrast (washout) and these features known as classic feature. HCC diagnosis depends on the imaging modality used in detection of tumor size<sup>[7]</sup>.

Early detection of HCC would reduce the risk of developing carcinogenesis. At this stage, HCC would be demonstrated as hypo-vascular because the arterial feeding has not fully developed. Lesions of less than 2 cm must be detected because delaying diagnosis decreases the treatment efficiency or increases the chance of tumor recurrences. The optimum management of nodules with diameters of less than 1 cm that shows the HCC model has not yet been demonstrated. Thus, the biopsy should be applied whenever the technical condition is suitable<sup>[27]</sup>. However, biopsy has many disadvantages; it is not an optimal choice in all cases, it is rather expensive, it can cause pain and anxiety, there are sampling errors particularly for small lesions, and of course there are bleeding complications.

### 1. HCC diagnosis in CT and MRI

Previous studies have shown that the sensitivity is higher in MRI compared to CT. The sensitivity depends on tumor size; MRI has a 62% sensitivity while CT has a 48% sensitivity for detecting small lesions less than 2 cm versus 95 % in MRI and 92% in CT for detecting lesions more than 2 cm. Previous studies have also shown that the sensitivity of gadoxetic acid-enhanced MRI is greater than multiphasic CT while the specificity is the same, especially for small lesions<sup>[28]</sup>. The big difference in detection was in lesions less than 1 cm, where the sensitivity of MRI was higher than CT. However, the specificity for both modalities was low<sup>[29]</sup>.

In MRI, the HCC shows a hyper-intensity in T2-weighted and diffusion-weighted images. The gadoxetic acid or gadobenate dimeglumine contrast media used in MRI have a higher sensitivity than with extracellular agents<sup>[28]</sup>. The gadoxetic acid has a unique feature in hepatic cells, just 50% of the injection dose is absorbed by hepatocytes and excreted by bile ducts, while the other 50% is excreted by the kidneys. This feature has a consequence in the diagnostic field: one of this, in the late dynamic phase gained 3 minutes. Thus, in this period the concentration would be combined between extracellular and hepatocellular so that the lesion will appear as hypo-intensity looks like washout. The second consequence, the hypo-intensity lesions seen in the hepatobiliary phase indicates a decrease in membrane transporters not related to the washout phenomenon. Therefore, the washout or capsule appearance of gadoxetic acid contrast can cause the only diagnosis in the portovenous phase<sup>[30]</sup>. A scientist has developed a new contrast media that is specifically used in MRI. The gadolinium-ethoxybenzyl-diethylenetriamine pentaacetic acid (Gd-EOB-DTPA, Primovist or Eovist) enhanced MRI detecting the nodules both of HCC and high-grade dysplastic nodules (HGDNs). The hypointense nodules seen in the hepatobiliary phase and not related to HCC is considered as a high risk of HCC progression compared with the hyperintense or isointense nodules. The image quality would be decreased because of the respiratory motion artefact, which is produced in the arterial phase. Thus, the lesions through this phase would be missed.

Liver nodules, more than 1 cm should be scanned with dynamic

MDCT or MRI without the need for biopsies especially in cirrhotic patients or in chronic hepatitis B patients when the vascular pattern is distinctive. Moreover, if the vascular pattern is not distinguishing, biopsies should be performed. However, the Gd-EOB-DTPA, should be completed before any biopsy procedure<sup>[31]</sup>.

### 2. Contrast-enhanced ultrasound

The Contrast-enhanced ultrasound (CEUS) has a possibility of risk misdiagnosis between HCC and new nodules in cirrhosis especially in nodules related to cholangiocarcinoma (CC). The HCC and CC follow a pattern by washout at CEUS, and this would reduce the accuracy of diagnosis. The washout of CC would happen earlier than 60 s after the injection, and the washout intensity in the portal phase is more remarkable compared with HCC. Thus, HCC can be detected by late (> 60 s) washout after contrast injection<sup>[27]</sup>.

CEUS has more specificity than CT and MRI for diagnosing the difference between CC and HCC within the 10-20 mm nodules, while the sensitivity is less than both of CC and HCC. However, the highest sensitivity and specificity for CEUS to detect the 20-30 mm nodules were noticed<sup>[27]</sup>. In addition, CEUS can be considered more effective in identifying the lesions in cirrhosis. The contrast media used in CEUS such as sulfur hexafluoride and octafluoropropane combined with a phospholipid shell has a short arterial phase, so the liver exploration is not adequate to visualize the deep lesions. The problem with CEUS is that the images acquired cannot be reviewed once the images are acquired, unlike CT and MRI. CEUS was recommended in the lesions - other than HCC - that shown in CT/MRI. Moreover, another contrast media used in the US such as the sinusoid - CEUS which used to detect the lesions that have a very late washout because using Kupffer phase. However, the combination of CEUS and contrast enhanced MRI is recommended for nodules between 1 and 2 cm.

### 3. Value of FDG-PET

<sup>18</sup>F-fluorodeoxyglucose positron emission tomography hybrid with computed tomography (FDG PET/CT) is a helpful tool used in molecular imaging to detect the stages of cancer tissue. In HCC patients, the FDG avidity is a tool used as a prognostic indicator of a primary and aggressive tumor that get together with tumor recurrence and pathological markers<sup>[32]</sup>.

HCC is one of the tumors that uptake FDG-PET but not too high. <sup>11</sup>C-choline have been suggested as another tracer other than <sup>18</sup>F-FDG to detect HCC. However, the results obtained was less than the contrast-enhanced CT and MRI. So far, the <sup>18</sup>F-FDG-PET uptake can be used in the prognosis of HCC, even though it can be associated with poor results. The aim of <sup>18</sup>F-FDG-PET uptake is that it can be used to help select the patients for liver resection (LR) or liver transplantation (LT)<sup>[11,33]</sup>.

The sensitivity of <sup>18</sup>F-FDG PET/CT is less than 70%. Moreover, the uptake of <sup>18</sup>F-FDG in HCC is highly variable, also the <sup>18</sup>F-FDG uptake is high in normal liver tissue. Thus, the difference between HCC and normal liver tissue looks to be limited. The standardized uptake values (SUVs) of HCC associates with the serum AFP are considered high.

## STAGING OF HCC

The management and prognosis of HCC follow one classification known as the Child-Turcotte-Pugh (CTP) classification, and it depends on tumor burden, patient's liver function and liver performance status. CTP classification is used to understand the HCC staging.

Many systems can be used to detect the HCC staging such as Barcelona Clinic Liver Cancer (BCLC), Japan Integrated staging (JIS), Cancer of Liver Italian Program (CLIP) score and American Joint Committee on Cancer (AJCC) to estimate the liver dysfunction severity<sup>[35]</sup> but their performance in outcome prediction is unclear. We aimed to investigate 10 currently used liver function models in HCC patients undergoing radiofrequency ablation (RFA). However, the most widely used staging systems are BCLC and AJCC system.

The BCLC system classification in both the staging and the treatments methods depending on both the tumor status (number, size, N1, M1, and vascular invasion) and liver function (liver function preservation, portal hypertension, and bilirubin). Figure 3 shows the stage, treatment methods and survival period for HCC which affiliate BCLC system.

According to BCLC system, the first stage of the HCC is very early stage (BCLC stage 0) which known as a single tumor less than 2cm without the vascular invasion and with conserved liver function (Child-Pugh A class patient with no any ascites). Early HCC (BCLC stage A) can define as the patient who has a single tumor less than 2 cm or three nodules all of them less than 3 cm with well-preserved liver function, and no clinically significant portal hypertension.

The intermediate HCC (BCLC stage B) can be defined as a multinodular asymptomatic tumor without extrahepatic spread and without vascular invasion. Also, the large solitary less than 5 cm with an expansive growth undergoes this stage. Moreover, this stage includes the patients who have a Child-Pugh A-B with refractory ascites, bacterial peritonitis, and encephalopathy. The advanced HCC (BCLC stage C) is retained to the patients with cancer symptoms (symptomatic tumors), macrovascular invasion, and extrahepatic spread (metastases). While the final stage (the end-stage of HCC) is represented for patients who have a severe tumor related disability, and there is no treatment option can be provided in this stage.

The second widely used system for determining the staging of HCC is AJCC, the new 8th edition staging system (Table 1), which uses the T classifications. The HCC were categorized as; T1a for the solitary tumors less or equal to 2 cm with or without vascular invasion, T1b for the solitary tumors more than 2 cm with or without vascular invasion. T2 classified as larger solitary tumors more than 2cm and less than 5 cm with vascular invasion as well as multifocal tumors. Next classified is T3 where contains multifocal tumors at

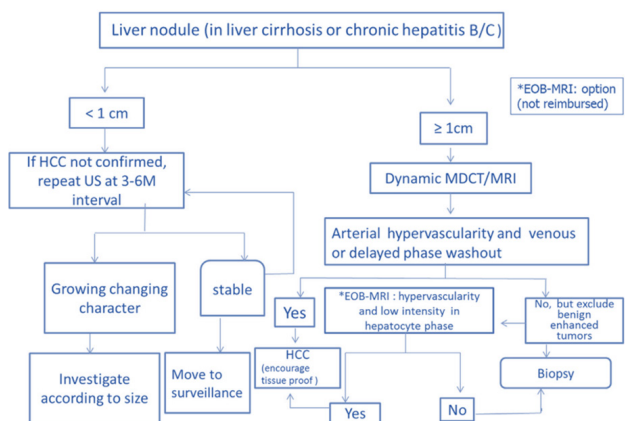
least one of them is more than 5 cm, while the T4 disease related to major vascular invasion<sup>[37]</sup>.

## SURVEILLANCE OF HCC

The purpose of surveillance is to reduce the number of deaths from HCC. Thus, diagnosis in the early stages enhances the therapies used and leads to improved treatment and is cost-effective. HCC surveillance depends on the tumor growth rate, tumor incidence in the target population, final functional status, overall health, and patient's age<sup>[38]</sup>.

Ultrasound is one of the most widely used methods for surveillance and monitoring of the HCC patients. It can also be used to observe other diseases which are developed within the development stage in HCC such as ascites, portal hypertension and portal vein thrombosis<sup>[39]</sup> as confirmed by resection. Case presentation: A 64-year-old man was referred to our hospital for suspected HCC. Contrast-enhanced computed tomography (CECT). The sensitivity of examination reaches 58 to 89% with a specificity of more than 90%. However, the US examination has less sensitivity to detect early stage of HCC and less effectiveness to detect small tumor lesions because of liver echotexture.

The HCC surveillance can also be detected by CT and MRI. Despite the high cost of examination compared with ultrasound, it is useful in patients in whom it cannot be achieved by US, especially in



**Figure 2** Diagnostic algorithm for suspected HCC. MDCT, MRI, US, and biopsy [31].

**Table 1** HCC Staging System by AJCC 8th Edition[37].

	Primary tumour (T)	Regional lymph nodes (N)	Distant metastases (M)
T1a	Solitary tumour < 2 cm with/without vascular invasion	Nx: Regional lymph nodes cannot be assessed	M0: No distant metastasis
T1b	Solitary tumour > 2 cm without vascular invasion	N0: No regional lymph node metastasis	M1: Distant metastasis
T2	Solitary tumour > 2 cm with vascular invasion or multifocal tumours, none > 5 cm	N1: Regional lymph node metastasis	
T3	Multifocal tumours at least one of which is > 5 cm		
T4	Single tumour or multifocal tumours of any size involving a major branch of the portal vein or hepatic vein or tumour(s) with direct invasion of adjacent organs other than the gallbladder or with perforation of visceral peritoneum		
Stage			
Stage IA	T1a	N0	M0
Stage IB	T1b	N0	M0
Stage II	T2	N0	M0
Stage IIIA	T3	N0	M0
Stage IIIB	T4	N0	M0
Stage IVA	Any T	N1	M0
Stage IVB	Any T	Any N	M1

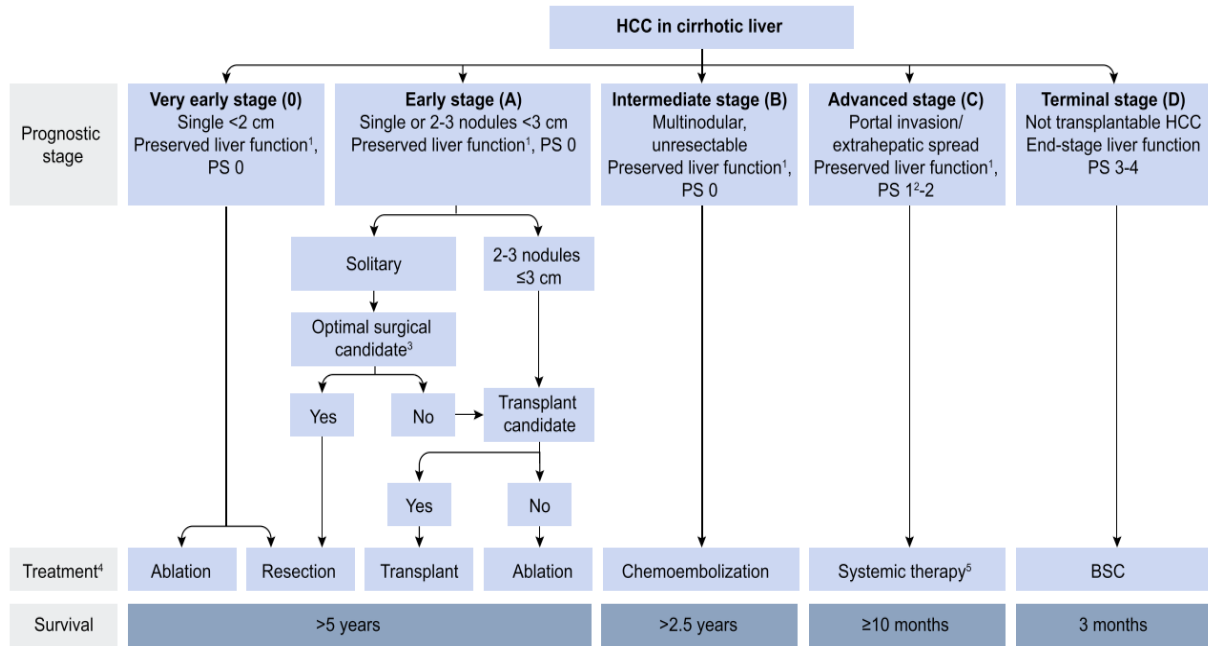


Figure 3 BCLC staging system for HCC. Prognostic stage, treatment methods and survival period [36].

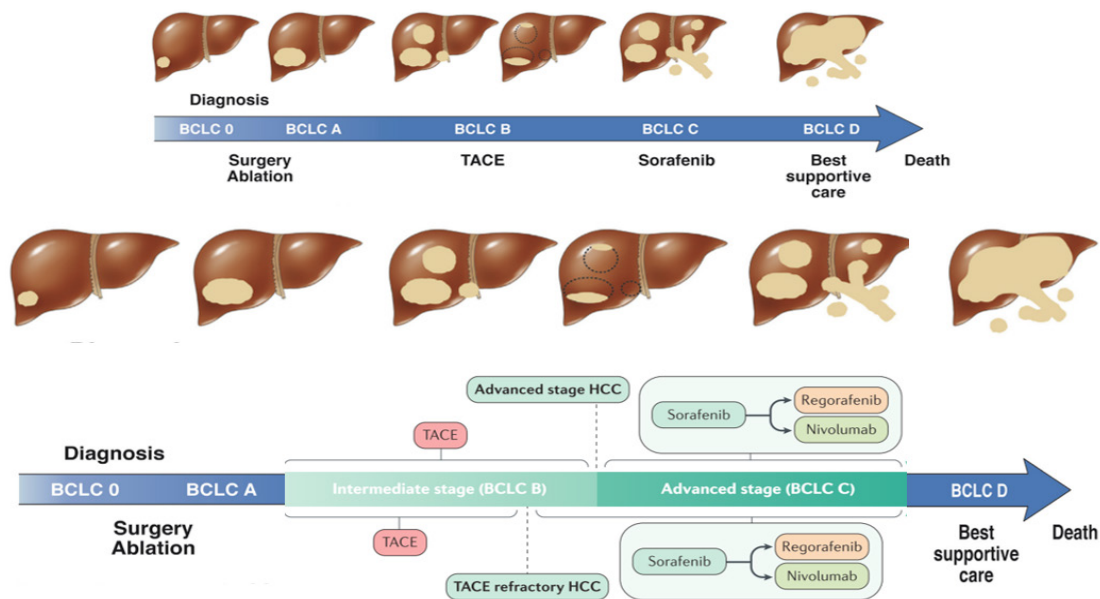


Figure 4 HCC treatment related to stages.

patients who are obese or have intestinal gas. Moreover, many non-invasive liver function models can be used to assess the hepatic injury severity due to the HCC development such as the albumin-bilirubin (ALBI) grade, platelet-albumin-bilirubin (PALBI) grade, and albumin-to-alkaline phosphatase ratio (AAPR). Another model can also be used to assess the liver dysfunction in HCC know as model for an end-stage liver disease (MELD) which depends on prothrombin, creatinine and serum bilirubin<sup>[35]</sup> but their performance in outcome prediction is unclear. We aimed to investigate 10 currently used liver function models in HCC patients undergoing radiofrequency ablation (RFA).

In addition, the BALAD score is another model that can be used for surveillance, prediction of the survival, and recurrence of HCC. BALAD consists of 5 serum biomarkers, the Bilirubin and Albumin is used to assess the remnant liver function, while the other three biomarkers related to serum tumor biomarkers are: AFP, Des-

Gamma-Carboxy Prothrombin (DCP), and Lens culinaris agglutinin-reactive AFP (AFP-L3)<sup>[40]</sup>. AFP is considered as an oncofetal protein also known as alpha-fetoglobulin. A raised level of AFP is a sign of increasing HCC risk factor, but the raised level of AFP is not an accurate indicator in all cases. Only a small percentage (10-20%) of early tumor stage can be detected by increasing AFP serum levels. Also, AFP is considered as a widely HCC biomarker proposed for prediction of HCC recurrence<sup>[40,41]</sup> it is necessary to establish a comprehensive panel of HCC biomarkers related to tumour behaviour and cancer prognosis. Resected HCCs from 251 patients were stained for hepatic progenitor cell (HPC). These tumor markers have a low sensitivity for detection early stage of HCC. However, the combination of two or more markers would enhance the early stage diagnostic<sup>[31]</sup>.

The European Association for the Study of the Liver (EASL) recommended that the US and AFP should be used every six months as a surveillance system. They were represented as a reasonable

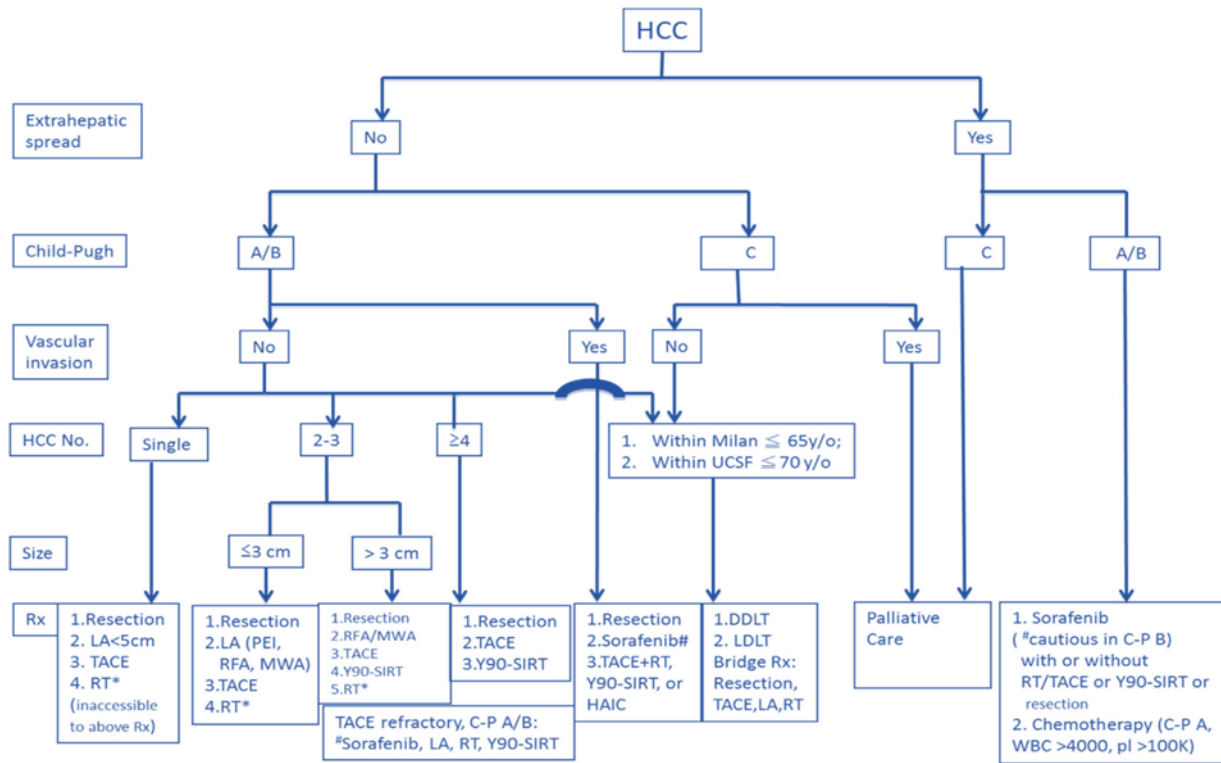


Figure 5 The surgical treatment planning [31].

choice and a suitable period to see the HCC development especially for early-stage and shorter survival<sup>[43]</sup>. Moreover, the Japan Society of Hepatology (JSH) have recommended the surveillance should be combining between US and tumor markers at least three markers including AFP, DCP, and AFP-L3. US have a high sensitivity and specificity comparing with AFP level and can be detected by the lesion with a small diameter which reaches to 1 cm. The US examination also recommended for the patient who have HCV and cirrhosis within 3 months<sup>[5]</sup>. CT and MRI with multiphasic contrast-enhanced are bespoken to assess the response after treatment.

## HCC TREATMENT AND MANAGEMENT

The HCC treatment depends on the hepatic function and planning of therapy that classified according to the specific system is known as Child-Pugh system. The Child-Pugh system is grading of chronic liver disease and given information about liver severity. The system was developed in 1973 and depends on five factors: thrombin time, albumin, total bilirubin, Ascites and hepatic encephalopathy. Prothrombin time and albumin are tests of the liver sympathetic functions; a failing liver cannot produce enough clotting factors in albumin. Total bilirubin reflects the liver’s ability to eliminate bilirubin via the bile duct. Ascites and encephalopathy are symptoms resulting in liver failure. Ascites is an accumulation of the fluid in the peritoneal cavity caused by increased pressure in the portal vein due to cirrhosis. Hepatic encephalopathy is a change in mental status caused by the build-up ammonia and other waste products that are usually removed by the liver. For Child-Pugh score system, patients are scored based on the values of their prothrombin time which are usually expressed as INR. The total bilirubin, the albumin concentration and then the severity of the ascites and encephalopathy. The score range from 5 to 15 with 15 being the worst (A 5-6 score, well compensated; B 7-9 score, significant functional compromise; and C 10-15 score, decompensated)<sup>[44]</sup>. The type of treatment used in HCC depends on many

pre-treatment evaluations factors such as tumor number, tumor size, tumor location, the presence of liver disease, major vascular invasion and lymph node metastasis.

### 1. Early stage treatment

In the early HCC stage, the curative treatment is applied and it can be achieved by LR, LT, radiofrequency ablation (RFA) or radiation segmentectomy (RS). The LR used to treat the very early stage with single nodule less than 2cm, while LT and RFA early stage with some nodules less than 3 and the size less than 3 cm. The LR still unsatisfying results with more than 70% of recurrent patient cancer. However, the advantage of surgical resection can demonstrate the early recurrence of the cancer tissue by pathology including the microvascular invasion. The survival for a long-term is achieved through surgical treatment. However, less than 20% of patients can do the surgical operations. Therefore, the non-surgical patients undergo to different treatment strategies such as RFA, percutaneous ethanol injection, selective internal radiation therapy (SIRT), stereotactic body radiation therapy (SBRT), laser induced thermotherapy (LITT), electromagnetic tracked laparoscopic ultrasound (ELUS) and chemoembolization<sup>[32]</sup>.

The LT can be applied for HCC patients, which have a single tumor less than 5 cm in diameter or the patient who have three nodules each one not more than 3 cm in diameter and without major vascular invasion (Milan criteria). It can also be applied for patients with a high-risk recurrence of cancer cells which found in the LR<sup>[10]</sup>. However, the recurrence of tumor in LT reaches to 20%, and this would have happened because the inability of preoperative radiological procedures to determine the tumor numbers and sizes and prediction of tumor’s aggressiveness.

Also, the RFA of lesions is less than 2 cm and have been demonstrated to complete ablation in more than 90% of cases and a recurrence rate of less than 1%<sup>[45]</sup>. The RFA can also be applied for HCC with a diameter less than 7 cm. However, the multiple ablations



increase the likelihood of tumors recurrence. The metastasis will take place through the vascular spread. Thus, the adjuvant therapy was advanced to improve the outcomes such as Lyso-thermosensitive liposomal doxorubicin (LTLTD) due to quickly diffuses in the local tissues around the tumor cells by rapid heat released through the liposomes<sup>[46]</sup>. LTLTD locally releases a high concentration of doxorubicin. We aimed to determine whether adding LTLTD improves the efficacy of radiofrequency ablation (RFA).

The RS is one of the methods of curative treatment which represents an option for early-stage treatment in the patient who cannot do the liver ablation and LT. This method is more effective in a long term outcome more than 10 years comparing with RFA, LR and LT which have a 5 years period of treatment<sup>[47]</sup>.

The early diagnosis of HCC gives a good chance to provide the suitable treatment and improvement the survival. However, the tumor recurrence occurs in 30% from the patients treated by the curative treatment<sup>[48]</sup> randomized, open-label, phase 3 trial of the efficacy and safety of adjuvant immunotherapy with activated CIK cells (created by incubation of patients' peripheral blood mononuclear cells with interleukin 2 and an antibody against CD3).

## 2. Intermediate stage

Most patients who have history of cancer and are not candidates for treatment using resection or transplant, thus, the big categories for options of the patient is loco-regional therapy (LRT), which essentially means therapy targeted to the liver. There are different types of LRT have been used, while the trans-arterial chemoembolization (TACE) is the most common<sup>[49]</sup>.

TACE is a minimally invasive procedure that uses many anti-cancer agents. They include intra-arterial infusion of chemotherapy (usually cisplatin or doxorubicin) mixed with lipiodol and gelatin sponge particle which injects into liver tumors through a catheter to treat cancers. TACE used to treat asymptomatic patients and the intermediate stage of the HCC. The procedure involves the injection of chemotherapy filled microspheres inside the artery that feeds a tumor. A catheter is inserted into the femoral artery and advanced until it reaches to the common hepatic artery, once the catheter is accurately positioned an angiogram is performed to visualize the tumor. Microspheres are injected into the catheter and released inside the feeder vessels, these microspheres slow blood flow as they travel and settle in the surface vessels and interior vessels of the tumor. Simultaneously, the microspheres start to controlled release of chemotherapy, this process is sustained over 14 days. Shrinkage and necrosis the tumor can be seen four to six weeks after the procedure<sup>[50,51]</sup> which elicits a sustained therapeutic response. DESIGN Time-of-flight mass cytometry and next-generation sequencing (NGS).

Anti-angiogenesis treatments are the process of making the new blood vessels in a person with cancer, this process creates new blood vessels that give a tumor its own blood supply and allow it to grow. Anti-angiogenic drugs target against blood vessels that tumor needs to survive. Treatment can be given intravenously or oral, as the drugs travels through the body it targets specific molecules associated with the tumor is vessels. Anti-angiogenic drugs inhibit vessel growth and cause existing vessels to undergo a process of normalization. As the vessels normalize their numerous branches regress and straight reducing blood supply to the tumor. Shrinkage and necrosis the tumor result the normalization process.

Because Anti-angiogenic drugs and chemoembolization works differently, sometimes they can be given together. Tumor vessels normalized when given anti-angiogenic drugs, these normalized vessels may provide a better route for microspheres to reach more of the

tumor, the combination of both therapies may work better than using each therapy alone and may help people with liver cancer live longer.

Stereotactic body radiotherapy (SBRT) is used when the LT, LR and RFA not suitable in HCC treatment. The aim of this strategy is to focus on damage to cancer cells while keeping healthy cells intact. SBRT is applied in patients with lesions which is located near to the central portal area and close to hepatic vessels and near to the biliary system. SBRT is primarily used in the patients with small HCC who cannot undergo to surgery, RFA, or transplantation<sup>[52]</sup>.

## 3. Advanced stage

Sorafenib is considered as the first oral multi-kinase inhibitor, its effect on serine/ threonine and receptor tyrosine kinases and used to treat both of tumor cells and tumor vasculature. Through the signal transduction process, the signals from the outside and within the cell are transferred to the nucleus by using protein known as RAS protein. Thus, the signal transduction pathways respond to cellular proliferation, angiogenesis, and cellular death. The RAS pathway contains MAPK protein kinase cascade. The latter consists of three kinases RAF, MEK and extracellular signal- regulated kinase (ERK). Through the growth regulating cascade, all of these kinases helps to transmit the signals from the membrane to the cell nucleus<sup>[34]</sup>. In the nucleus, the transcription factors are activated which regulate genes such as cell differentiation and growth genes where the regulation is controlled in normal cells. In the cancer cells, the transmit messages are continuously deregulated the cellular proliferation, and this occurred through overexpression of upstream and downstream effectors such as RAS or RAF. The sorafenib is applied to targets the RAF pathway so that the cell proliferation can be controlled. The cell growth factors such as VEGFR and PDGF are activated by the angiogenic process hence the blood cell growth, tube formation, and migration would increase. The sorafenib exerts an anti-angiogenic. Thus, the growth of blood vessels is prevented, and that would happen through the blockade of the receptor tyrosine kinases VEGFR2 to VEGFR3, PDGFR, RET, KIT, and TGF- $\beta$  and their associated signalling cascade including the RAF, MAKK, ERK pathway. Therefore, the tumor cell proliferation and tumor angiogenesis would be controlled<sup>[53,54]</sup>. Sorafenib is used to treat the advanced stage of the HCC. However, sorafenib has some limitations such as low response rate, complex mechanism following acquired resistance, little survival advantage, and high-level of individual response heterogeneity<sup>[55]</sup>.

Another oral multi-kinase inhibitor is Regorafenib (commercial name known as Stivarga) and Nivolumab which is not considered as an oral multi-kinase inhibitor which are targeted the angiogenic and oncogenic receptor tyrosine kinase (RTK). Regorafenib has been noticed to affect the VEGFR2-TIE2 tyrosine kinase inhibition. However, the molecular composition is like Sorafenib. Regorafenib is used with patients who have been treated with sorafenib before. Thus, it can be used to treat the advanced stage of HCC. The combination of Regorafenib and Nivolumab after Sorafenib treatment is still under experimentation and research is still underway to prove its validity in the treatment of phase III in HCC<sup>[56]</sup>. However, Figure 4 shown the treatment methods of HCC related to the stages.

Radioembolization is another option of treatment which intra-arterial injection of microspheres is loaded with yttrium-90. The 90Y has a half-life 2.67 days and the ability of penetration into tissues between 2.5-11 mm. There are two types of 90Y available glass and resin microspheres and can attach to small beads. Moreover, the 90Y technique immunizing the post-embolization incident. However, this technique has many complications such as jaundice, sinusoidal obstruction syndrome, moderate cholestasis, and ascites. In summary,

the following paragraphs gives guideline and treatments option for HCC for all of the parameters needed for Child-Pugh stage, vascular invasion, HCC number and sizes.

There are another treatment methods that can be used for specific inhibitors such as lenvatinib (inhibitor of VEGFR 1-3, PDGF, KIT, and RET), ramucirumab, tivantinib (inhibitor of c-Met positivity), and cabozantinib (inhibitor of VEGFR2, MET, and RET).

## CONCLUSION

For the Conclusion, I have done some minor editing as follows: The present review summarized the current knowledge hepatocellular carcinoma, its molecular biology and risk factors, as well as the art in the diagnosis and treatment of the disease. However, detailed information about the HCC mechanism in the invasion of neighboring cells and metastasis are not yet fully understood. Future studies should focus on determining their mechanisms and identifying potential diagnostic and therapeutic strategies in HCC. The understanding of HCC will not improve by itself the efficiency of chemo or radiotherapy. A better understanding of the disease could lead to a better choice of treatment for each patient, or the development of more effective or safer treatment. Therefore, a deeper understanding of HCC might bring breakthroughs and transformative changes in the diagnosis and treatment of HCC in the future.

## REFERENCES

- Xu JH, Chang WH, Fu HW, Yuan T, Chen P. The mRNA, miRNA and lncRNA networks in hepatocellular carcinoma: An integrative transcriptomic analysis from Gene Expression Omnibus. *Mol. Med. Rep.* 2018; **17**(5): 6472-6482. [PMID: 29512731]; [PMCID: PMC5928629]; [DOI: 10.3892/mmr.2018.8694]
- Coulouarn C, Clément B. "Stellate cells and the development of liver cancer: Therapeutic potential of targeting the stroma," *J. Hepatol.* 2014; **60**(6): 1306-1309. [PMID: 24530649]; [DOI: 10.1016/j.jhep.2014.02.003]
- Younossi Z, Loomba R, Rinella M, Bugianesi E, Marchesini B. Dual Role for Inositol-requiring Enzyme 1 $\alpha$  in Promoting the Development of Hepatocellular Carcinoma during Diet-induced Obesity. *Hepatology* 2017; **5**: 1-36. [DOI: 10.1002/hep.29871]
- Piñero F, Pages J, Marciano S, Fernández N, Silva J, Anders M, Zerega A, Ridruejo E, Ameigeiras B, D'Amico C, Gaité L, Bermúdez C, Cobos M, Rosales C, Romero G, McCormack L, Reggiardo V, Colombato L, Gadano A, Silva M. Fatty liver disease, an emerging etiology of hepatocellular carcinoma in Argentina. *World J. Hepatol.* 2018; **10**(1): 41-50. [PMID: 29399277]; [PMCID: PMC5787683]; [DOI: 10.4254/wjh.v10.i1.41]
- Axley P, Ahmed Z, Ravi S, Singal AK. Hepatitis C Virus and Hepatocellular Carcinoma: A Narrative Review. *J. Clin. Transl. Hepatol.* 2018; **6**(2): 1-6. [PMID: 29607308]; [PMCID: PMC5863002]; [DOI: 10.14218/JCTH.2017.00067]
- Pinato DJ, Sharma R, Citti C, Platt H, Ventura-Cots M, Allara E, Chen TY, Dalla Pria A, Jain M, Mínguez B, Kikuchi L, Kaufman West E, Merli M, Kaplan DE, Hasson H, Marks K, Nelson M, Núñez M, Aytaman A, Bower M, Bräu N, Liver Cancer in HIV Study Group. The albumin-bilirubin grade uncovers the prognostic relationship between hepatic reserve and immune dysfunction in HIV-associated hepatocellular carcinoma. *Aliment. Pharmacol. Ther.* 2018; **47**(1): 95-103. [PMID: 29034998]; [DOI: 10.1111/apt.14356]
- Li Y, Wang LH, Zhang HT, Wang YT, Liu S, Zhou WL, Yuan XZ, Li TY, Wu CF, Yang JY. Disulfiram combined with copper inhibits metastasis and epithelial-mesenchymal transition in hepatocellular carcinoma through the NF- $\kappa$ B and TGF- $\beta$  pathways. *J. Cell. Mol. Med.* 2018; **22**(1): 439-451. [PMID: 29148232]; [PMCID: PMC5742719]; [DOI: 10.1111/jcmm.13334]
- Friedman SL. Hepatic Stellate Cells: Protean, Multifunctional, and Enigmatic Cells of the Liver. *Physiol. Rev.* 2008; **88**(1): 125-172. [PMID: 18195085]; [PMCID: PMC2888531]; [DOI: 10.1152/physrev.00013.2007]
- Coulouarn C, Corlu A, Glaise D, Guénon I, Thorgeirsson SS, Clément B. "Hepatocyte-stellate cell cross-talk in the liver engenders a permissive inflammatory microenvironment that drives progression in hepatocellular carcinoma," *Cancer Res.* 2012; **72**(10): 2533-2542. [PMID: 22419664]; [PMCID: PMC3498759]; [DOI: 10.1158/0008-5472.CAN-11-3317]
- Najjar M, Agrawal S, Emond JC, Halazun KJ. Pretreatment neutrophil-lymphocyte ratio: useful prognostic biomarker in hepatocellular carcinoma." *J. Hepatocell. carcinoma* 2018; **5**: 17-28. [PMID: 29404284]; [PMCID: PMC5779314]; [DOI: 10.2147/JHC.S86792]
- Bouattour M, Raymond E, Qin S, Cheng AL, Stammberger U, Locatelli G, Faivre S. Recent developments of c-Met as a therapeutic target in hepatocellular carcinoma," *Hepatology* 2018; **67**(3): 1132-1149. [PMID: 28862760]; [PMCID: PMC5873445]; [DOI: 10.1002/hep.29496]
- Chan AJ, Balderramo D, Kikuchi L, Ballerga EG, Prieto JE, Tapias M, Idrovo V, Davalos MB, Cairo F, Barreyro FJ, Paredes S, Hernandez N, Avendaño K, Ferrer JD, Yang JD, Carrera E, Mattos AZ, Hirsch BS, Gonçalves PT, Carrilho FJ, Roberts LR, Debes JD. Early Age Hepatocellular Carcinoma Associated With Hepatitis B Infection in South America. *Clin. Gastroenterol. Hepatol.* 2017; **15**(10): 1631-1632. [PMID: 28532694]; [DOI: 10.1016/j.cgh.2017.05.015]
- Ho DW, Lo RC, Chan LK, Ng IO. Molecular Pathogenesis of Hepatocellular Carcinoma. *Liver Cancer* 2016; **5**(4): 290-302. [PMID: 27781201]; [PMCID: PMC5075835]; [DOI: 10.1159/000449340]
- Gan W, Yi Y, Fu Y, Huang J, Lu Z, Jing C, Fan J, Zhou J, Qiu S. Fibrinogen and C-reactive protein score is a prognostic index for patients with Hepatocellular carcinoma undergoing curative resection: A prognostic nomogram study." *J. Cancer* 2018; **9**(1): 148-156. [PMID: 29290780]; [PMCID: PMC5743722]; [DOI: 10.7150/jca.22246]
- Du Z, Dong J, Bi J, Bai R, Zhang J, Wu Z, Lv Y, Zhang X, Wu R. Predictive value of the preoperative neutrophil-to-lymphocyte ratio for the development of hepatocellular carcinoma in HBV-associated cirrhotic patients after splenectomy. *PLoS One* 2018 Apr 5; **13**(4): e0195336. [PMID: 29621282]; [PMCID: PMC5886527]; [DOI: 10.1371/journal.pone.0195336]
- Ringelhan M, Pfister D, O'Connor T, Pikarsky E, Heikenwalder M. The immunology of hepatocellular carcinoma. *Nat. Immunol.* 2018; **19**(March): 1-11. [PMID: 29379119]; [DOI: 10.1038/s41590-018-0044-z]
- Hu B, Ding GY, Fu PY, Zhu XD, Ji Y, Shi GM, Shen YH, Cai JB, Yang Z, Zhou J, Fan J, Sun HC, Kuang M, Huang C. NOD-like receptor X1 functions as a tumor suppressor by inhibiting epithelial-mesenchymal transition and inducing aging in hepatocellular carcinoma cells. *J. Hematol. Oncol.* 2018; **11**(1): 1-13. [PMID: 29482578]; [PMCID: PMC5828065]; [DOI: 10.1186/s13045-018-0573-9]
- Zhang L, Wu GY, Wu YJ, Liu SY. The serum metabolic profiles of different Barcelona stages hepatocellular carcinoma associated with hepatitis B virus," *Oncol. Lett.* 2018 Jan; **15**(1): 956-962. [PMID: 29399157]; [PMCID: PMC5772915]; [DOI: 10.3892/ol.2017.7393]
- X. Wu, J. M. Vierling, and L. Beretta, "Mutations in Plasma DNA in Patients With Hepatocellular Carcinoma or Cirrhosis : Prevalence and Risk Factors," *HEPATOLOGY* 2018; **00**(00): 1-14. [DOI: 10.1002/hep4.1187]
- Dhanasekaran R, Gabay-Ryan M, Baylot V, Lai I, Mosley A,

- Huang X, Zabludoff S, Li J, Kaimal V, Karmali P, Felsher DW. Anti-miR-17 therapy delays tumorigenesis in MYC-driven hepatocellular carcinoma (HCC). *Oncotarget* 2018; **9**(5): 5517-5528. [PMID: 29464015]; [PMCID: PMC5814155]; [DOI: 10.18632/oncotarget.22342]
21. Wong CM, Tsang FH, Ng IO. Non-coding RNAs in hepatocellular carcinoma: Molecular functions and pathological implications,” *Nat. Rev. Gastroenterol. Hepatol.* 2018; **15**(3): 137-151. [PMID: 29317776]; [DOI: 10.1038/nrgastro.2017.169]
  22. DeWaal D, Nogueira V, Terry AR, Patra KC, Jeon SM, Guzman G, Au J, Long CP, Antoniewicz MR, Hay N. Author Correction: Hexokinase-2 depletion inhibits glycolysis and induces oxidative phosphorylation in hepatocellular carcinoma and sensitizes to metformin. *Nat. Commun.* 2018 Jun 26; **9**(1): 2539. [PMID: 29946147]; [PMCID: PMC6018736]; [DOI: 10.1038/s41467-018-04182-z]
  23. Masuda K, Ono A, Aikata H, Kawaoka T, Nelson Hayes C, Teraoka Y, Daijo K, Nakamura-Inagaki Y, Morio K, Fujino H, Kan H, Uchida T, Masaki K, Kobayashi T, Nakahara T, Makokha GN, Zhang Y, Nagaoki Y, Miki D, Tsuge M, Hiramatsu A, Imamura M, Abe-Chayama H, Kawakami Y, Ochi H, Chayama K. Serum HMGB1 concentrations at 4 weeks is a useful predictor of extreme poor prognosis for advanced hepatocellular carcinoma treated with sorafenib and hepatic arterial infusion chemotherapy. *J. Gastroenterol.* 2018; **53**(1): 107-118. [PMID: 28474222]; [DOI: 10.1007/s00535-017-1348-8]
  24. Song BN, Chu IS. A gene expression signature of FOXM1 predicts the prognosis of hepatocellular carcinoma,” *Exp. Mol. Med.* 2018; **50**(1): e418. [PMID: 29303511]; [PMCID: PMC5992987]; [DOI: 10.1038/emm.2017.159]
  25. Wang B, Hsu CJ, Chou CH, Lee HL, Chiang WL, Su CM, Tsai HC, Yang SF, Tang CH. Variations in the AURKA Gene : Biomarkers for the Development and Progression of Hepatocellular Carcinoma. *Int. J. Med. Sci.* 2018 Jan 1; **15**(2): 170-175. [PMID: 29333101]; [PMCID: PMC5765730]; [DOI: 10.7150/ijms.22513]
  26. Ying H, Xu Z, Chen M, Zhou S, Liang X, Cai X. “Overexpression of Zwint predicts poor prognosis and promotes the proliferation of hepatocellular carcinoma by regulating cell-cycle-related proteins,” *Oncotargets. Ther.* 2018 Feb 2; **11**: 689-702. [PMID: 29440916]; [PMCID: PMC5800459]; [DOI: 10.2147/OTT.S152138]
  27. Schellhaas B, Görtz RS, Pfeifer L, Kielisch C, Neurath MF, Strobel D. Diagnostic accuracy of contrast-enhanced ultrasound for the differential diagnosis of hepatocellular carcinoma: ESCULAP versus CEUS-LI-RADS. *Eur. J. Gastroenterol. Hepatol.* 2017; **29**(9): 1036-1044. [PMID: 28562394]; [DOI: 10.1097/MEG.0000000000000916]
  28. Lee YJ, Lee JM, Lee JS, Lee HY, Park BH, Kim YH, Han JK, Choi BI. Hepatocellular Carcinoma: Diagnostic Performance of Multidetector CT and MR Imaging-A Systematic Review and Meta-Analysis. *Radiology* 2015; **275**(1): 97-109. [PMID: 25559230]; [DOI: 10.1148/radiol.14140690]
  29. Heimbach JK, Kulik LM, Finn RS, Sirlin CB, Abecassis MM, Roberts LR, Zhu AX, Murad MH, Marrero JA. AASLD guidelines for the treatment of hepatocellular carcinoma. *Hepatology* 2018; **67**(1): 358-380. [PMID: 28130846]; [DOI: 10.1002/hep.29086]
  30. Joo I, Lee JM, Lee DH, Jeon JH, Han JK, Choi BI. Noninvasive diagnosis of hepatocellular carcinoma on gadoxetic acid-enhanced MRI: can hypointensity on the hepatobiliary phase be used as an alternative to washout. *Eur. Radiol.* 2015; **25**(10): 2859-2868. [PMID: 25773941]; [DOI: 10.1007/s00330-015-3686-3]
  31. Surveillance group; Diagnosis group; Staging group; Surgery group; Local ablation group; TACE/TARE/HAI group; Target therapy/systemic therapy group; Radiotherapy group; Prevention group; Drafting group. Management consensus guideline for hepatocellular carcinoma: 2016 updated by the Taiwan Liver Cancer Association and the Gastroenterological Society of Taiwan,” *J. Formos. Med. Assoc.* 2018 May; **117**(5): 381-403. [PMID: 29074347]; [DOI: 10.1016/j.jfma.2017.09.007]
  32. Hyun SH, Eo JS, Song BI, Lee JW, Na SJ, Hong IK, Oh JK, Chung YA, Kim TS, Yun M. Preoperative prediction of microvascular invasion of hepatocellular carcinoma using 18F-FDG PET/CT: a multicenter retrospective cohort study. *Eur. J. Nucl. Med. Mol. Imaging* 2018; **45**(5): 720-726. [PMID: 29167923]; [DOI: 10.1007/s00259-017-3880-4]
  33. Castilla-Lièvre MA, Franco D, Gervais P, Kuhnast B, Agostini H, Marthey L, Désarnaud S, Helal BO. “Diagnostic value of combining 11C-choline and 18F-FDG PET/CT in hepatocellular carcinoma,” *Eur. J. Nucl. Med. Mol. Imaging* 2016; **43**(5): 852-859. [PMID: 26577938]; [DOI: 10.1007/s00259-015-3241-0]
  34. Sung PS, Park HL, Yang K, Hwang S, Song MJ, Jang JW, Choi JY, Yoon SK, Yoo IR, Bae SH. “18F-fluorodeoxyglucose uptake of hepatocellular carcinoma as a prognostic predictor in patients with sorafenib treatment,” *Eur. J. Nucl. Med. Mol. Imaging* 2018; **45**(3): 384-391. [PMID: 29124280]; [DOI: 10.1007/s00259-017-3871-5]
  35. Ho SY, Liu PH, Hsu CY, Chiou YY, Su CW, Lee YH, Huang YH, Lee FY, Hou MC, Huo TI. Prognostic Performance of Ten Liver Function Models in Patients with Hepatocellular Carcinoma Undergoing Radiofrequency Ablation,” *Sci. Rep.* 2018; **8**(1): 1-9. [PMID: 29339752]; [PMCID: PMC5770426]; [DOI: 10.1038/s41598-018-19251-y]
  36. P. R. Galle et al. “EASL Clinical Practice Guidelines: Management of hepatocellular carcinoma,” *J. Hepatol.* 2018. [DOI: 10.1016/j.jhep.2018.03.019]
  37. Kamarajah SK, Frankel TL, Sonnenday C, Cho CS, Nathan H. Critical evaluation of the American Joint Commission on Cancer (AJCC) 8th edition staging system for patients with Hepatocellular Carcinoma (HCC): A Surveillance, Epidemiology, End Results (SEER) analysis. *J. Surg. Oncol.* 2018 Mar; **117**(4): 644-650. [PMID: 29127719]; [DOI: 10.1002/jso.24908]
  38. Younossi Z, Loomba R, Rinella M, Bugianesi E, Marchesini B. Current and Future Therapeutic Regimens for Non-alcoholic Fatty Liver Disease (NAFLD) and Non-alcoholic Steatohepatitis (NASH),” *Hepatology* 2017; **5**: 1-36. [DOI: 10.1002/hep.29724]
  39. Goto Y et al. Complete spontaneous necrosis of hepatocellular carcinoma accompanied by portal vein tumor thrombosis: A case report. *Int. J. Surg. Case Rep.* 2018; **44**: 220-225. [DOI: 10.1016/j.ijscr.2018.02.045]
  40. Wongjarupong N, Negron-Ocasio GM, Chaiteerakij R, Addissie BD, Mohamed EA, Mara KC, Harmsen WS, Theobald JP, Peters BE, Balsanek JG, Ward MM, Giama NH, Venkatesh SK, Harnois DM, Charlton MR, Yamada H, Algeciras-Schimmich A, Snyder MR, Therneau TM, Roberts LR. Model combining pre-transplant tumor biomarkers and tumor size shows more utility in predicting hepatocellular carcinoma recurrence and survival than the BALAD models. *World J. Gastroenterol.* 2018; **24**(12): 1321-1331. [PMID: 29599607]; [PMCID: PMC5871827]; [DOI: 10.3748/wjg.v24.i12.1321]
  41. Nishioka ST, Sato MM, Wong LL, Tiirikainen M, Kwee SA. Clinical and molecular sub-classification of hepatocellular carcinoma relative to alpha-fetoprotein level in an Asia-Pacific island cohort. *Hepatology Res.* 2018; **4**(1): 1. [PMID: 29376136]; [PMCID: PMC5786161]; [DOI: 10.20517/2394-5079.2017.46]
  42. Seino S, Tsuchiya A, Watanabe Y, Kawata Y, Kojima Y, Ikarashi S, Yanai H, Nakamura K, Kumaki D, Hirano M, Funakoshi K, Aono T, Sakai T, Sakata J, Takamura M, Kawai H, Yamagiwa S, Wakai T, Terai S. Clinical outcome of hepatocellular carcinoma can be predicted by the expression of hepatic progenitor cell markers and serum tumour markers. *Oncotarget* 2018; **9**(31): 21844-21860. [PMID: 29774107]; [PMCID: PMC5955154]; [DOI: 10.18632/oncotarget.25074]
  43. Chon YE, Jung KS, Kim MJ, Choi JY, An C, Park JY, Ahn SH,

- Kim BK, Kim SU, Park H, Hwang SK, Rim KS, Han KH, Kim DY. Predictors of failure to detect early hepatocellular carcinoma in patients with chronic hepatitis B who received regular surveillance,” *Aliment. Pharmacol. Ther.* 2018; **47(8)**: 1201-1212. [PMID: 29492988]; [DOI: 10.1111/apt.14578]
44. Becker AK, Tso DK, Harris AC, Malfair D, Chang SD. Extrahepatic metastases of hepatocellular carcinoma: A spectrum of imaging findings. *Can. Assoc. Radiol. J.* 2014; **65(1)**: 60-66. [PMID: 24239313]; [DOI: 10.1016/j.carj.2013.05.004]
  45. Meijer B, Mulder CJ, de Boer NK. “NUDT15: A novel player in thiopurine metabolism,” *J. Gastrointest. Liver Dis.* 2016; **25(2)**: 261-262. [PMID: 27308664]; [DOI: 10.15403/jgld.2014.1121.252.nud]
  46. Tak WY, Lin SM, Wang Y, Zheng J, Vecchione A, Park SY, Chen MH, Wong S, Xu R, Peng CY, Chiou YY, Huang GT, Cai J, Abdullah BJJ, Lee JS, Lee JY, Choi JY, Gopez-Cervantes J, Sherman M, Finn RS, Omata M, O’Neal M, Makris L, Borys N, Poon R, Lencioni R. Phase III HEAT study adding lysos-thermosensitive liposomal doxorubicin to radiofrequency ablation in patients with unresectable hepatocellular carcinoma lesions. *Clin. Cancer Res.* 2018; **24(1)**: 73-83. [PMID: 29018051]; [DOI: 10.1158/1078-0432.CCR-16-2433]
  47. Lewandowski RJ, Gabr A, Abouchaleh N, Ali R, Al Asadi A, Mora RA, Kulik L, Ganger D, Desai K, Thornburg B, Mouli S1, Hickey R, Caicedo JC, Abecassis M, Riaz A, Salem R. Radiation Segmentectomy: Potential Curative Therapy for Early Hepatocellular Carcinoma. *Radiology.* 2018 Jun; **287(3)**: 1050-1058 [PMID: 29688155]; [DOI: 10.1148/radiol.2018171768]
  48. Lee JH, Lee JH, Lim YS, Yeon JE, Song TJ, Yu SJ, Gwak GY, Kim KM, Kim YJ, Lee JW, Yoon JH. Adjuvant immunotherapy with autologous cytokine-induced killer cells for hepatocellular carcinoma. *Gastroenterology* 2015; **148(7)**: 1383-1391.e6. [PMID: 25747273]; [DOI: 10.1053/j.gastro.2015.02.055]
  49. Kulik L, Heimbach JK, Zaiem F, Almasri J, Prokop LJ, Wang Z, Murad MH, Mohammed K. Therapies for patients with hepatocellular carcinoma awaiting liver transplantation: A systematic review and meta-analysis. *Hepatology* 2018; **67(1)**: 381-400. [PMID: 28859222]; [DOI: 10.1002/hep.29485]
  50. Biolato M, Gallusi G, Iavarone M, Cabibbo G, Racco S, De Santis A, Corte CD, Maida M, Attili AF, Sangiovanni A3, Cammà C4, La Torre G, Gasbarrini A, Grieco A. Prognostic ability of BCLC-B subclassification in patients with hepatocellular carcinoma undergoing transarterial chemoembolization. *Ann. Hepatol.* 2018; **17(1)**: 110-118. [PMID: 29311396]; [DOI: 10.5604/01.3001.0010.7542]
  51. Chew V, Lee YH, Pan L, Nasir NJM, Lim CJ, Chua C, Lai L, Hazirah SN, Lim TKH, Goh BKP, Chung A, Lo RHG, Ng D, Filarca RLF, Albani S, Chow PKH. “Immune activation underlies a sustained clinical response to Yttrium-90 radioembolisation in hepatocellular carcinoma,” *Gut.* 2019 Feb; **68(2)**: 335-346. [PMID: 29440463]; [PMCID: PMC6352403]; [DOI: 10.1136/gutjnl-2017-315485]
  52. Kubo K, Kimura T, Aikata H, Takahashi S, Takeuchi Y, Takahashi I, Nishibuchi I, Murakami Y, Chayama K, Nagata Y. Long-term outcome of stereotactic body radiotherapy for patients with small hepatocellular carcinoma. *Hepatol. Res.* 2018 Aug; **48(9)**: 701-707. [PMID: 29333633]; [DOI: 10.1111/hepr.13063]
  53. Kudo M, Finn RS, Qin S, Han KH, Ikeda K, Piscaglia F, Baron A, Park JW, Han G, Jassem J, Blanc JF, Vogel A, Komov D, Evans TRJ, Lopez C, Dutcus C, Guo M, Saito K, Kraljevic S, Tamai T, Ren M, Cheng AL. Lenvatinib versus sorafenib in first-line treatment of patients with unresectable hepatocellular carcinoma: a randomised phase 3 non-inferiority trial,” *Lancet* 2018; **391(10126)**: 1163-1173. [PMID: 29433850]; [DOI: 10.1016/S0140-6736(18)30207-1]
  54. J. Rimola et al. Complete response under sorafenib in patients with hepatocellular carcinoma: Relationship with dermatologic adverse events. *Hepatology* 2018; **67(2)**: 612-622. [DOI: 10.1002/hep.29515]
  55. Lyu N, Lin Y, Kong Y, Zhang Z, Liu L, Zheng L, Mu L, Wang J, Li X, Pan T, Xie Q, Liu Y, Lin A, Wu P, Zhao M. FOXAI: a phase II trial evaluating the efficacy and safety of hepatic arterial infusion of oxaliplatin plus fluorouracil/leucovorin for advanced hepatocellular carcinoma. *Gut* 2018; **67(2)**: 395-396. [PMID: 28592441]; [DOI: 10.1136/gutjnl-2017-314138]
  56. Wörns MA, Galle PR. Two large steps forward, one small step back,” *Nat. Rev. Gastroenterol. Hepatol.* 2018; **15(2)**: 74-76. [PMID: 29300046]; [DOI: 10.1038/nrgastro.2017.174]
- Peer Reivewers:** Nermine Ehsan; Cerwenka Herwig